

# 18<sup>th</sup> Asian Colloquium in Nephrology



*Best Practices in Kidney Care in Asia*

*19 – 21 July 2019*

**Incorporating:** SOTANC - State-Of-The-Art Nephrology Course (Nursing)  
Singapore Society of Nephrology Annual Scientific Meeting  
Asia Renal Association - Asian Nephrology Conference

## Non-Infectious Complications of Peritoneal Dialysis

Dr Sunita Bavanandan  
Department of Nephrology  
Hospital Kuala Lumpur



NEPHROLOGY  
HOSPITAL KUALA LUMPUR

# **Non-infectious complications of PD**

- TECHNICAL COMPLICATIONS
- METABOLIC COMPLICATIONS
- ENCAPSULATING PERITONEAL SCLEROSIS

# Outline

- TECHNICAL ( common)
  - ❖ Catheter related
  - ❖ Related to increased intrabdominal pressure:
    - Hernias
    - Leaks
    - Hydrothorax
  - ❖ Haemoperitoneum
  
- METABOLIC
  
- ENCAPSULATING PERITONEAL SCLEROSIS

# Catheter related complications

- High incidence
- Particularly in the early stages of starting PD  
*(Guo and Mujais 2003; Descoudres et al 2002; Lupo et al 1994; Kolesynk et al 2008)*
- First 3/12 - PD Catheter problems 15%  
Next 3-6/12 - 7% of patients  
After the first year – ↓ to 1% – 2% of pts  
*(Kolesynk et al 2008)*

Data from NECOSAD database  
38 dialysis centers in the Netherlands.

# Catheter dysfunction is a common early complication

**Table I. List of the early complications following Tenckhoff catheter insertion.**

Early complication (≤30 days)	Number of cases (% of total)	Number of catheters consequently removed (% of total)
Wound haematoma/infection	19 (38%)	3 (22%)
Malposition/poor flow	12 (24%)	6 (42%)
Exit site haematoma/infection	11 (22%)	2 (14%)
Early peritonitis	3 (6%)	3 (22%)
Pericatheter leakage	3 (6%)	0
Others	2 (4%)	0
<b>Total</b>	<b>50</b>	<b>14</b>

30%

TABLE 2

Types of Complications Post Tenckhoff Catheter Insertion

Complication type	Occurrences	
	(n)	(%)
Catheter migration	29	7.6
Catheter obstruction without migration	22	5.7
Exit-site infection	24	6.3
Leak from main incision	12	3.1
Culture-proven wound infection	14	3.6
Post-insertion peritonitis	11	2.9
Hemoperitoneum	1	0.3

16.4%

Tiong et al 2006

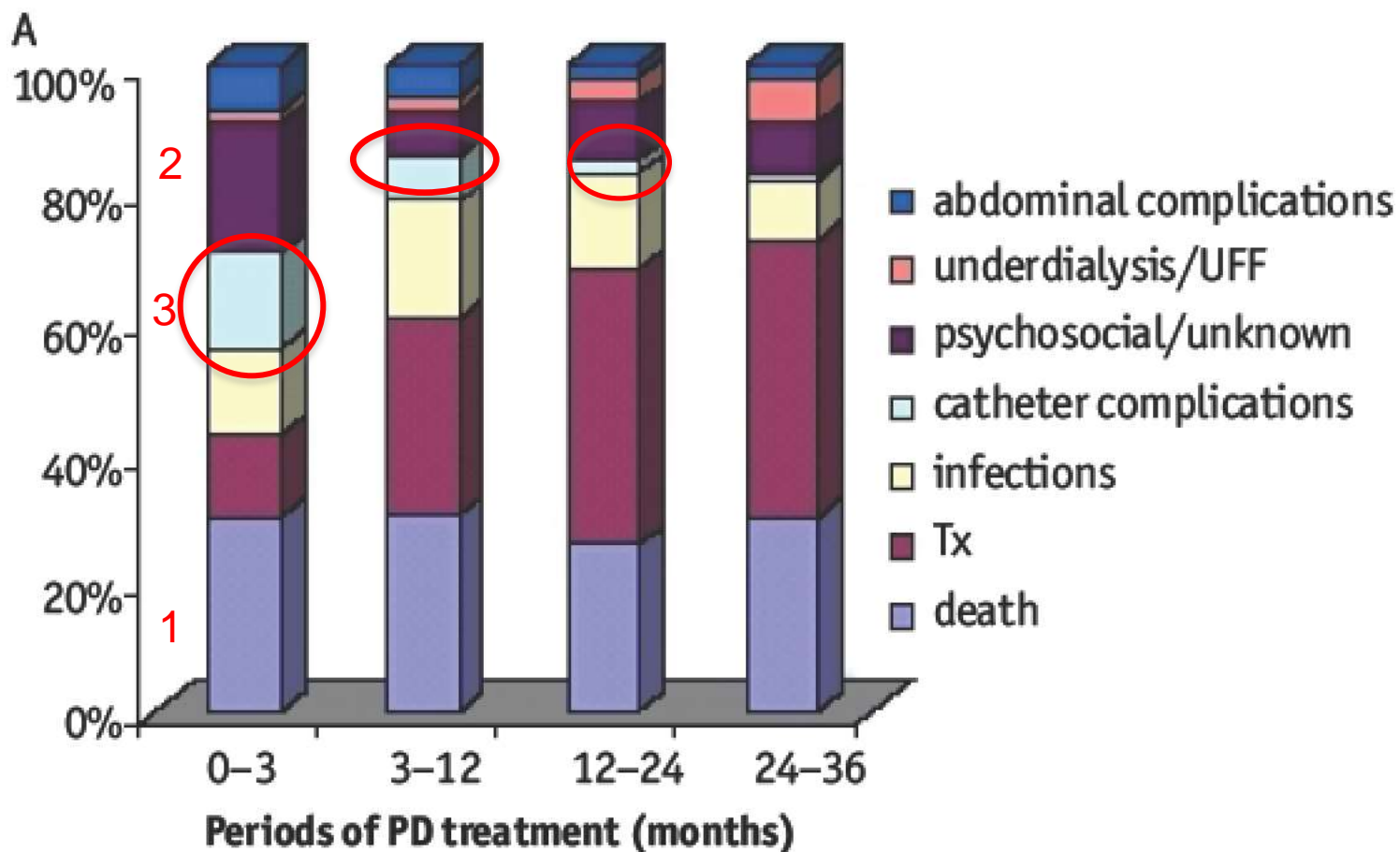


Liu and Hooi 2010



\* PD catheter malfunction contributes significantly to PD drop-out

KOLESNYK *et al.*



# PD catheter dysfunction

1. Obstruction
2. Malposition/Migration
3. Catheter-related pain

# Case Scenario 1

- 47 year old man ESRD had undergone PD catheter insertion in Hospital A.

2 weeks later he was admitted for CAPD training

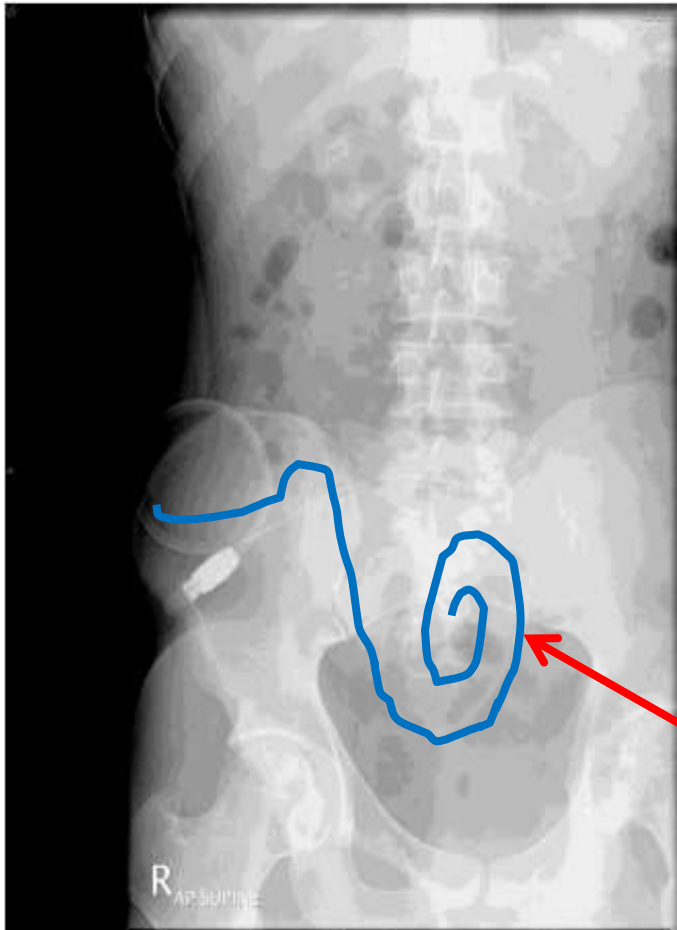
On the 2<sup>nd</sup> day of CAPD training, noted the inflow and outflow was poor.

What would you do next?



47 year old man ESRD had undergone a PD catheter insertion in Hospital A. 2 weeks later he was admitted for CAPD training: 4 exchanges a day. On the 1<sup>st</sup> day of CAPD training, noted the inflow and outflow was poor.

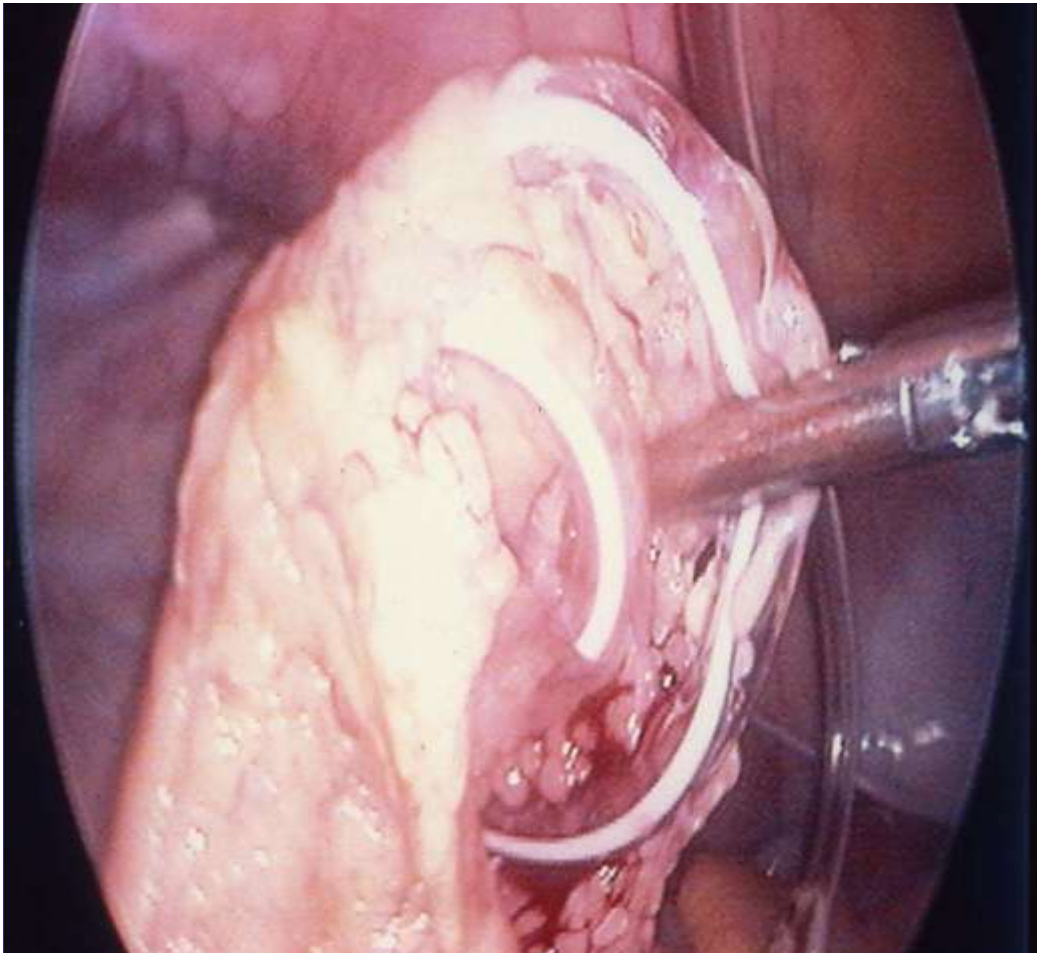
What would you do next?



AXR: PD catheter above pelvis  
Flow rate: Inflow 15 mins  
Outflow 45 mins

Tip of PD catheter

# Management



- Laxatives
  - Laparoscopic salvage : Omental wrap
- Omentopexy,  
repositioning of  
catheter
- Discharged well with  
no more flow problems

# Obstructed PD catheter flow

- Inflow and/or outflow obstruction more common as early complications
- Can also occur at any time, especially during/after episodes of peritonitis – inflammation, fibrin etc
- Need to ascertain the cause to determine the appropriate intervention

# Key assessment

- Observe dialysis exchange
- Determine type of obstruction:
  - \*outflow
  - \*inflow
  - \*both ways

# Outflow obstruction

May be due to:

- Catheter tip migration out of pelvis
- Omental wrap
- Constipation
- Mechanical blockage of transfer set or catheter
- Postimplantation blood clot or fibrin
- Extrinsic bladder compression due to urinary retention
- Catheter entrapment
- Epiploic appendices of colon
- Fallopian tubes
- Adhesions

# **Pseudo-obstruction**

## **– failure to drain**

1/ the first-ever infusion of dialysis fluid

- may not drain because of movement into the paracolic gutters, filling up the peritoneal “dead-space”

2/ leaks of dialysate out of the peritoneal cavity

# Inflow obstruction

May be due to:

- Mechanical blockage such as clamps or kinks in transfer set or catheter
- Post-implantation blood clot or fibrin ( particularly with peritonitis)

# Key activities

## 1. Examine

- PD catheter
- transfer set and dialysis equipment tubing

looking for clamps being applied or kinks

\*includes portions hidden by clothing and under dressings





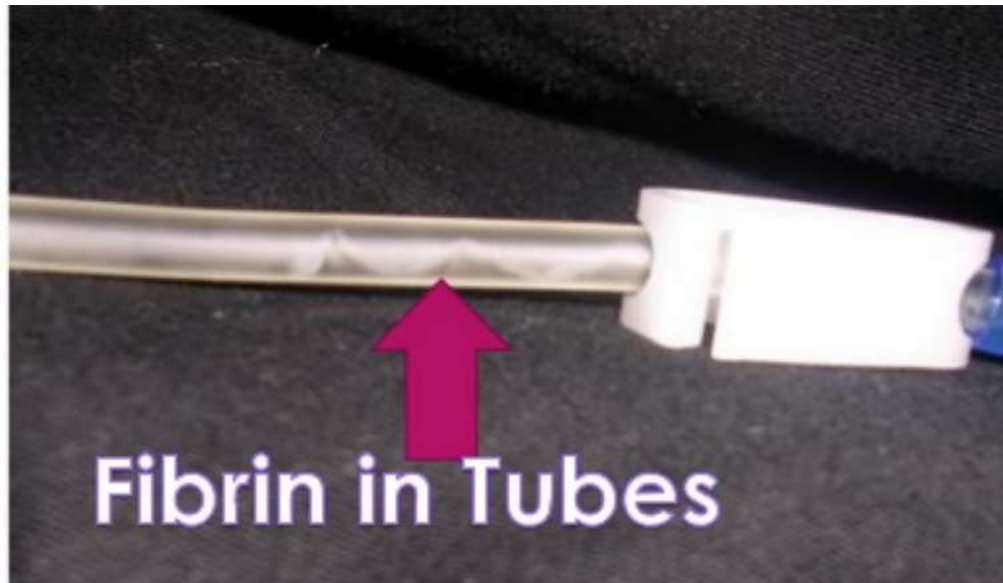
# First steps :

- Change body position
- Try to flush the catheter
- Correct constipation
- Obtain AXR, looking for
  - catheter position
  - faecal loading
  - subcutaneous and intraperitoneal catheter kink ( may need lateral XR)

# Management

## Clots/Fibrin in the catheter

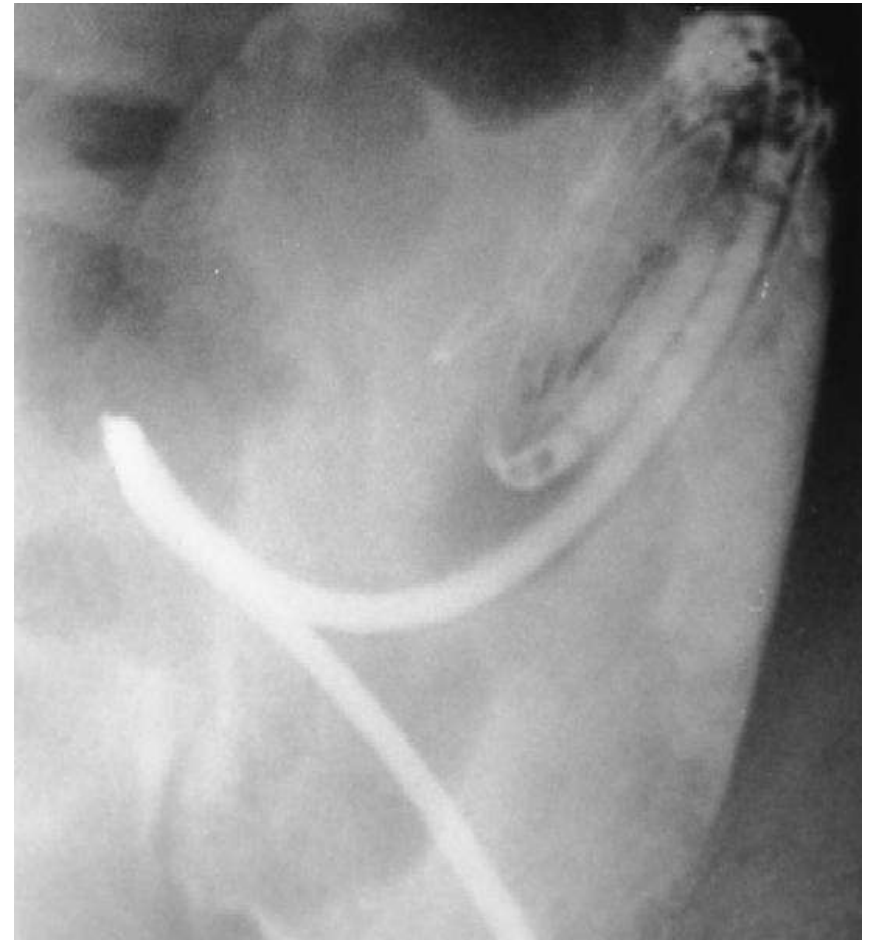
- Forceful irrigation by experienced PD personnel with dialysate or normal saline in a 50 mL syringe using moderate pressure (“push and pull” manoeuvre)
- Discontinue if patient has pain or cramping



# Clots/Fibrin in the catheter

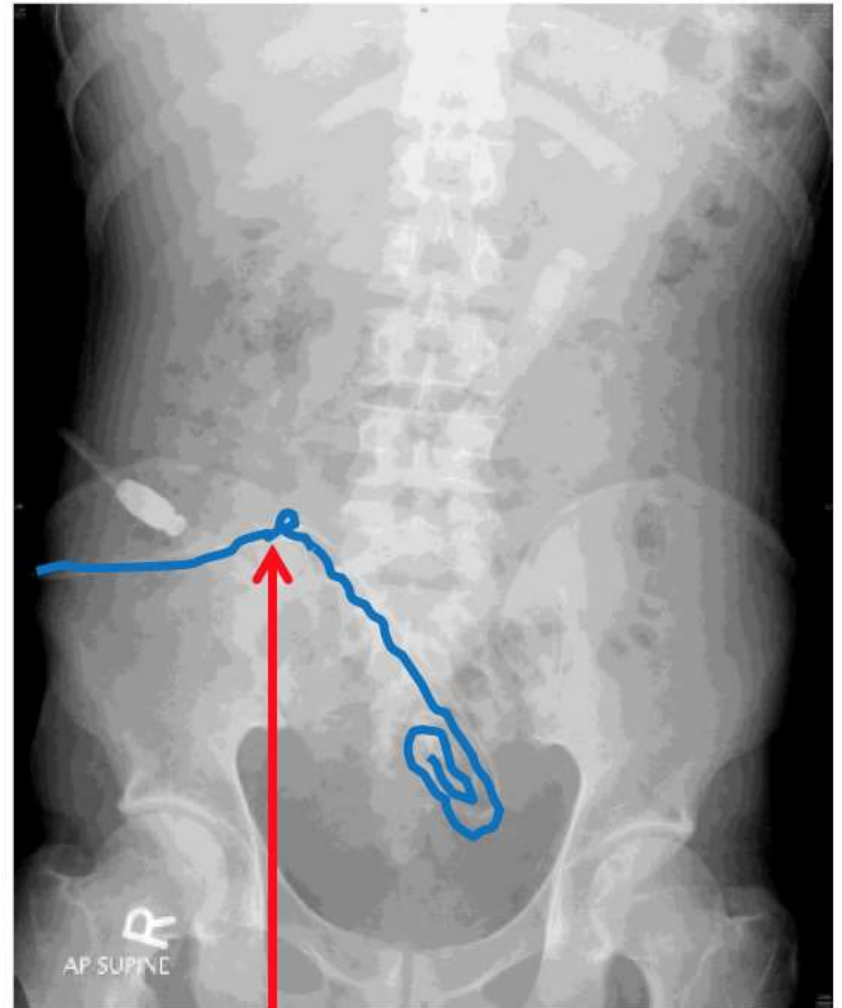
If occurring as a late complication

- Urokinase/TPA  
( not recommended )
- Laparoscopic milking of  
the clot in the catheter



# Kinking

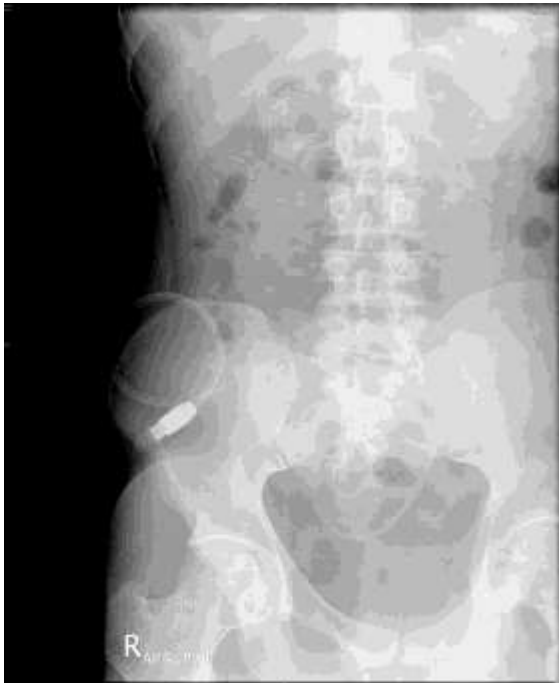1. if in subcutaneous tunnel:
  - A. at time of catheter insertion :  
simple correction on table
  - B. as a late complication :  
incision over the kink and  
reposition the catheter  
i.e. “ swing” to a new  
exit site
2. intraperitoneal : use a stiff  
guide wire advanced into the  
catheter under direct  
fluoroscopic control



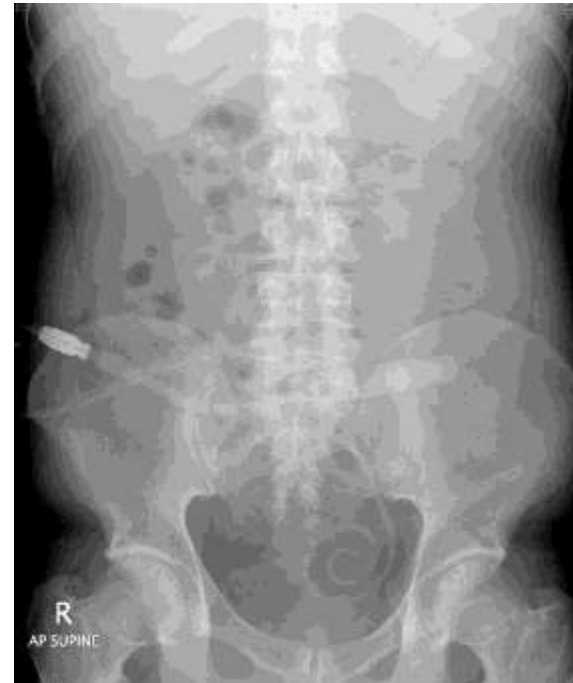kinking point

# Omental wrap/adhesions/occlusion of fenestrae

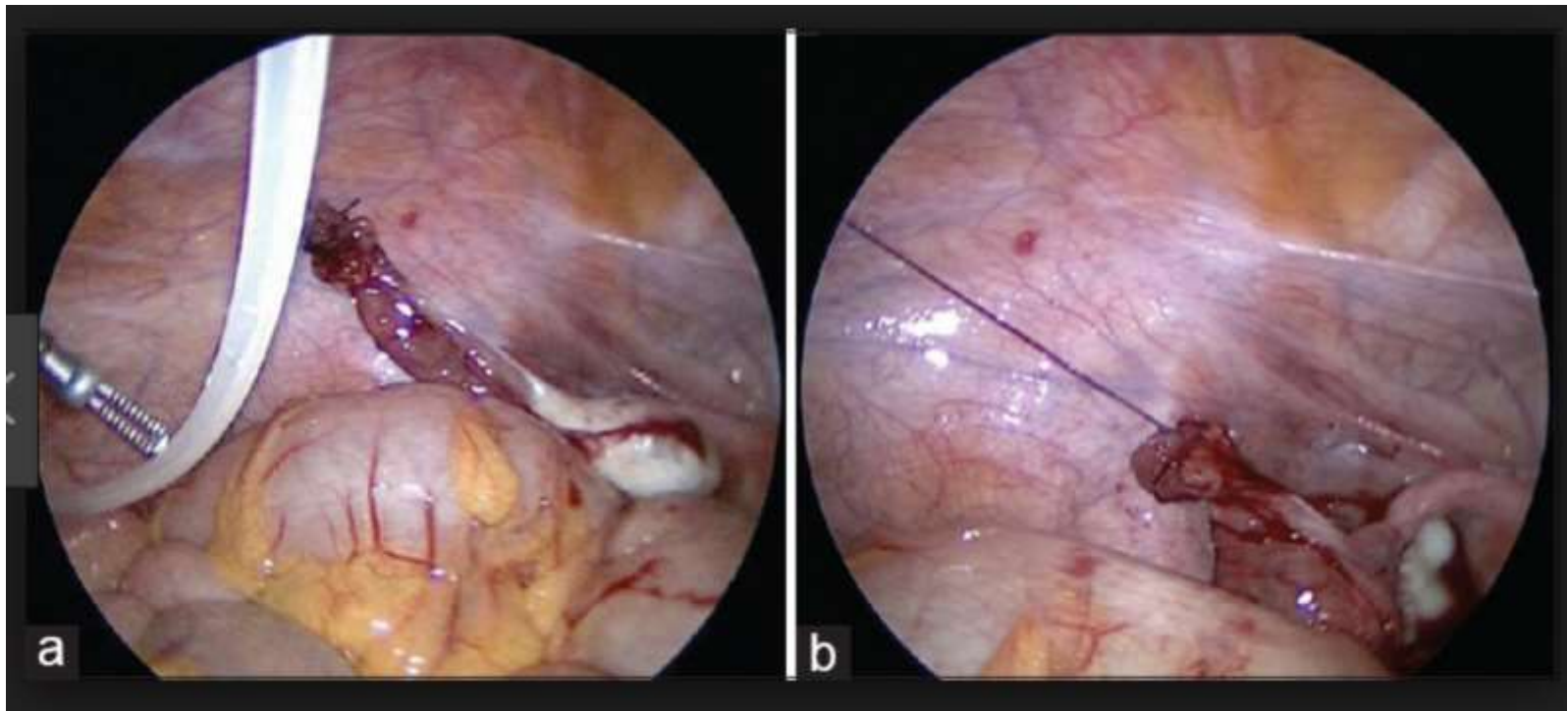
- diagnosed by laparoscopy ( or open rescue surgery)
- additional advantage of instantaneous Rx  
e.g. omentectomy or adhesiolysis



Pre Lap Salvage



Post Lap Salvage Anchoring to bladder

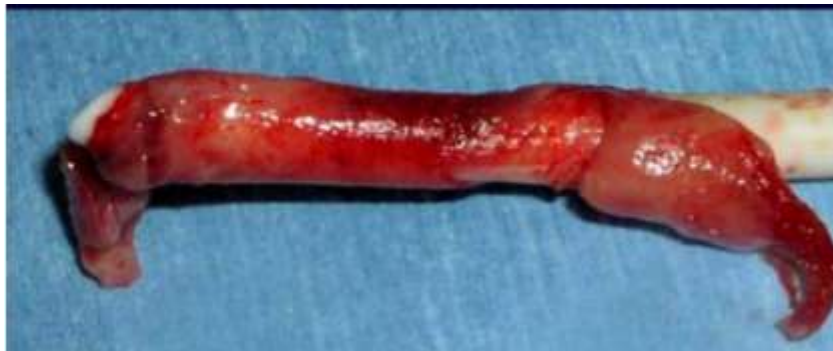

Laparoscopic oviductal fimbrioplasty for  
peritoneal dialysis catheter outflow  
obstruction caused by ovarian fimbriae

*Aldohayan et al .  
Saudi J Laparosc 2016;1:20-2*

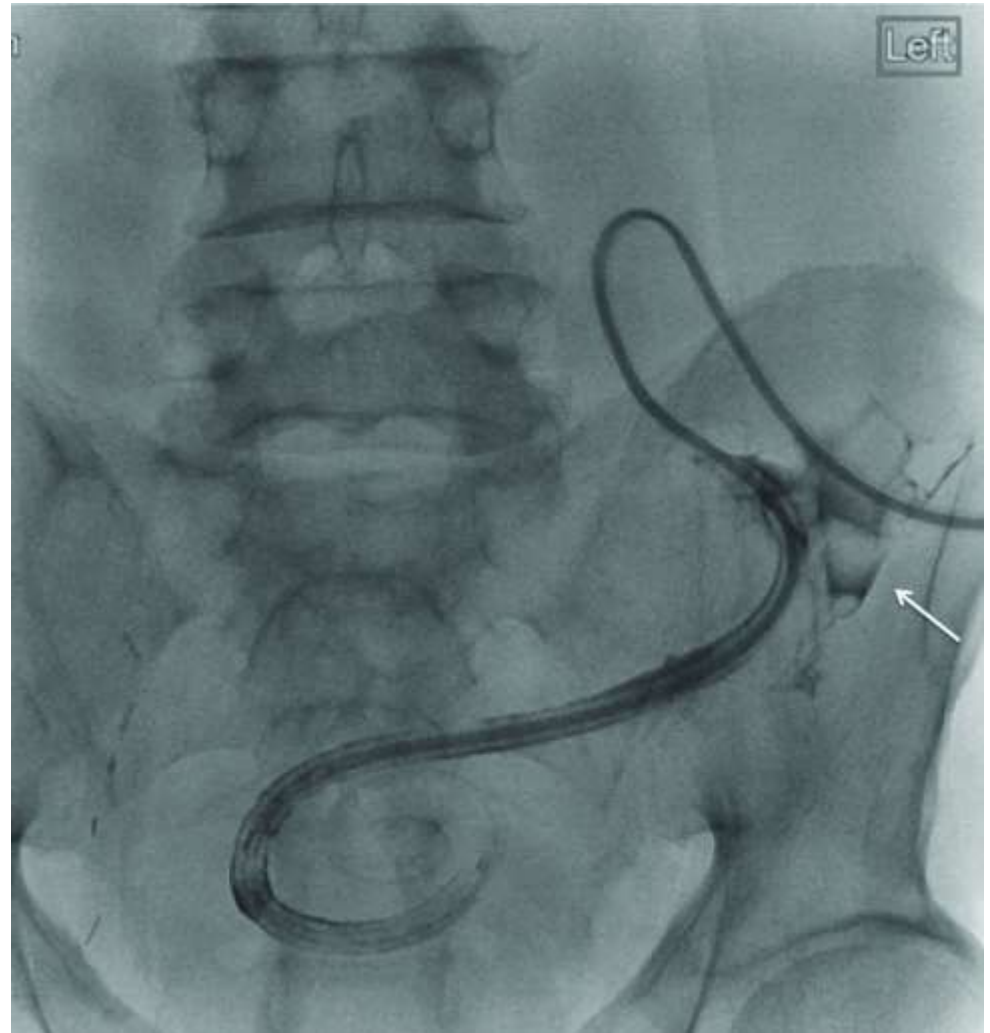
# Extraluminal fibrin sheath obstruction

- ?? Underappreciated problem
- PD catheter in good position but slow inflow, no outflow



# Case study of Extraluminal fibrin sheath obstruction

- Cathetogram
- Injected contrast tracking retrograde along the catheter to the site of spillage in LLQ





- A stiff guidewire was used to manipulate the catheter, displacing the catheter into L paracolic gutter → good flow

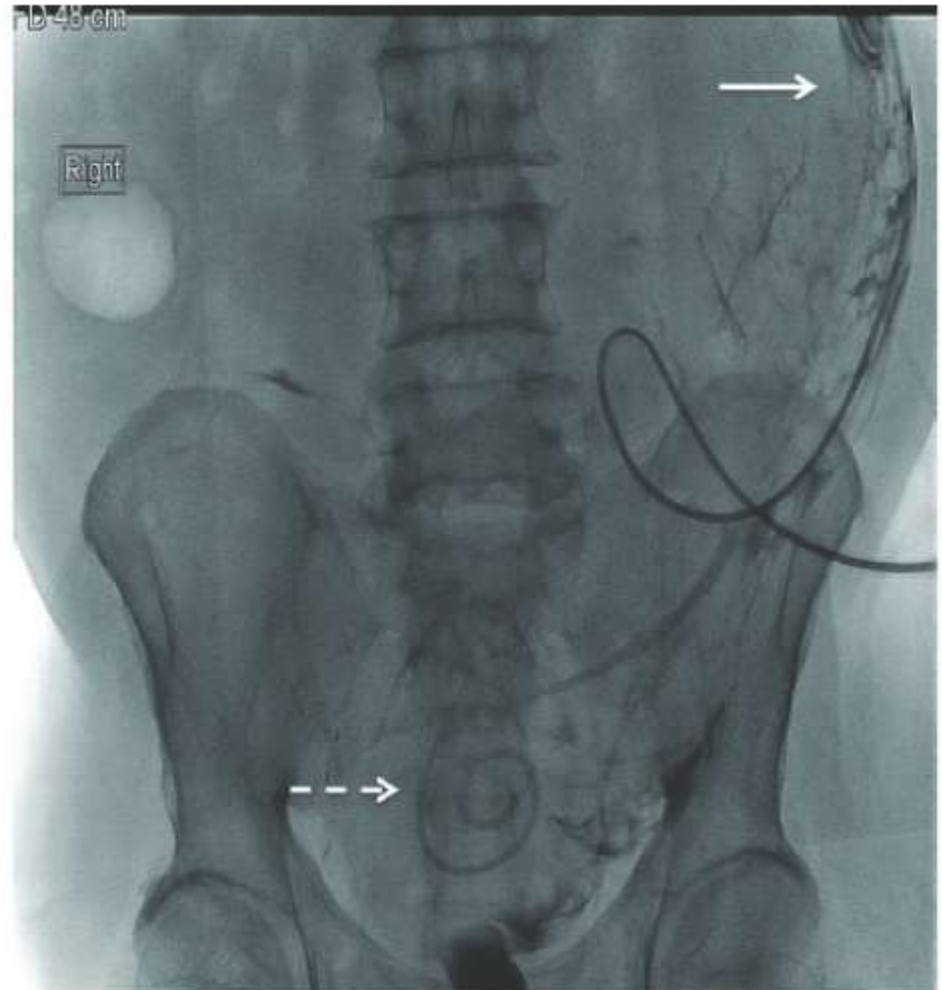


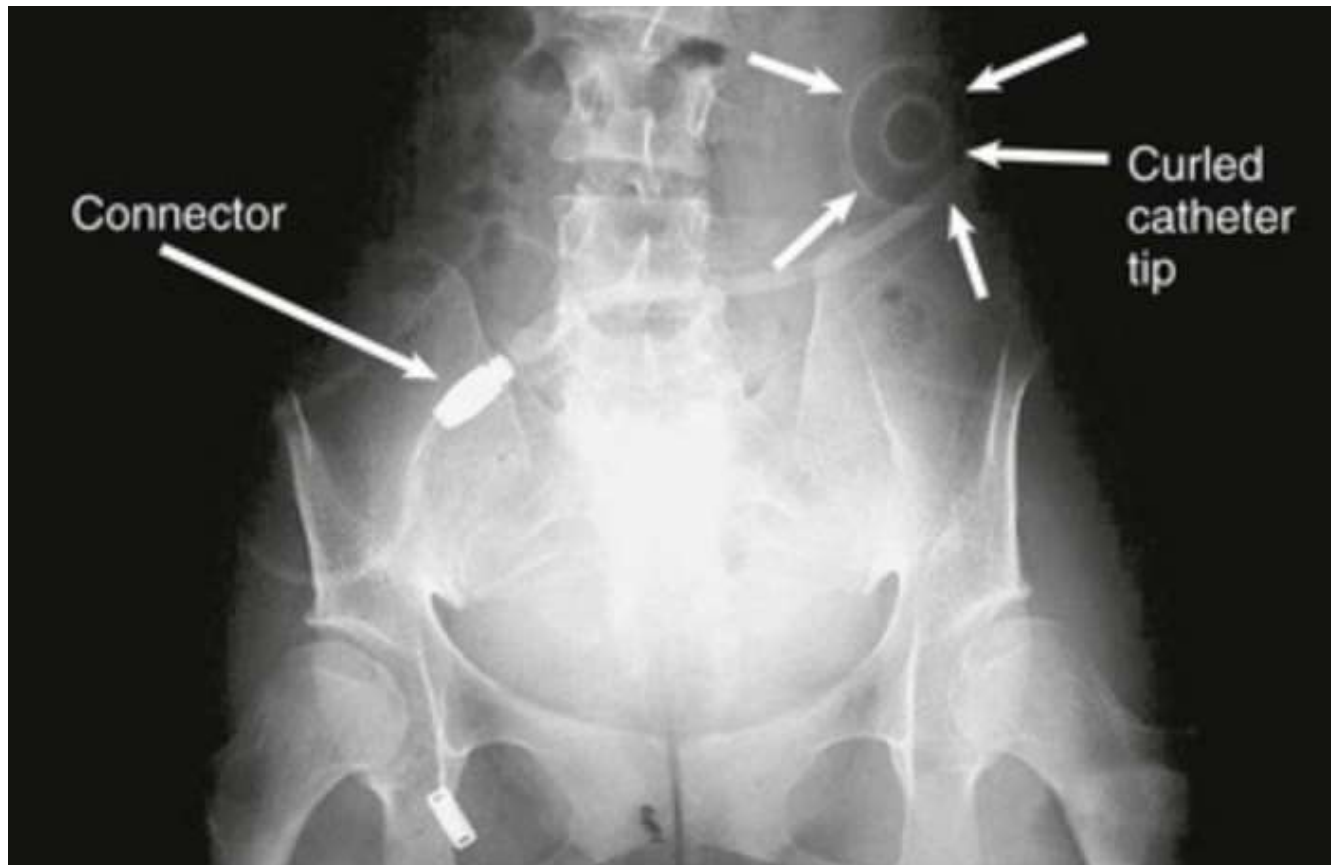
Figure 2 — After stiff-wire manipulation, the peritoneal dialysis catheter is visualized in its new position in the left paracolic gutter (white solid arrow). In the mid-pelvis, a contrast-filled fibrin sheath from the initial PD catheter placement is seen (white dashed arrow).

# PD catheter dysfunction

1. Obstruction
2. Malposition/Migration
3. Catheter-related pain

# PD Catheter malposition/migration

- Defined as when PD catheter tip is not located in the true pelvis



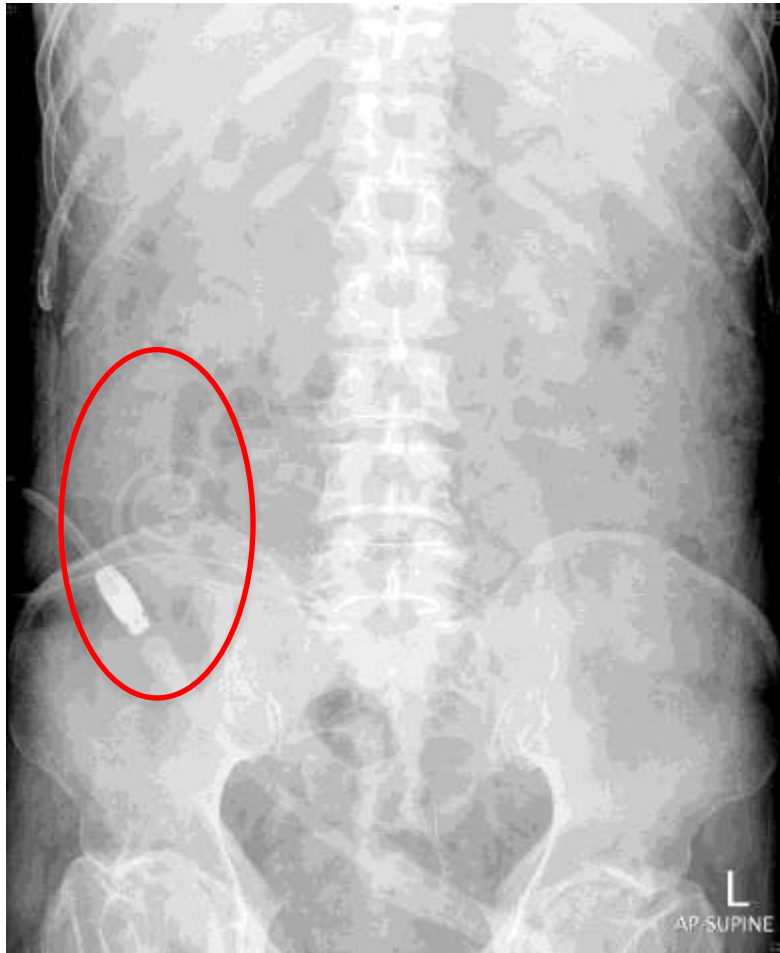# PD Catheter malposition/migration

- Predisposing factors:
  - Improper implantation/length
  - Direction of the tunnel and catheter memory
  - Constipation

NB : not all migrated/malpositioned caths  
cause problems

– if it FUNCTIONS WELL , leave it

# Catheter Malposition or Migration



## Step 1

Conservative Mx with laxatives.

## Step 2

- Refer Surgical for Laparoscopic salvage/
- Fluoroscopic catheter repositioning with a stiff guide wire or Fogarty catheter

## Step 3

DIY: Remove & Reinsert

# PD catheter dysfunction

1. Obstruction

2. Migration

2. Catheter-related pain

# Catheter-related pain

- Commonly (56-75%) occurs when catheter is first used (*Twardowski & Nichols, 2000*)
- Often presents as pain /cramping at end of drain
- May also occur at end of inflow

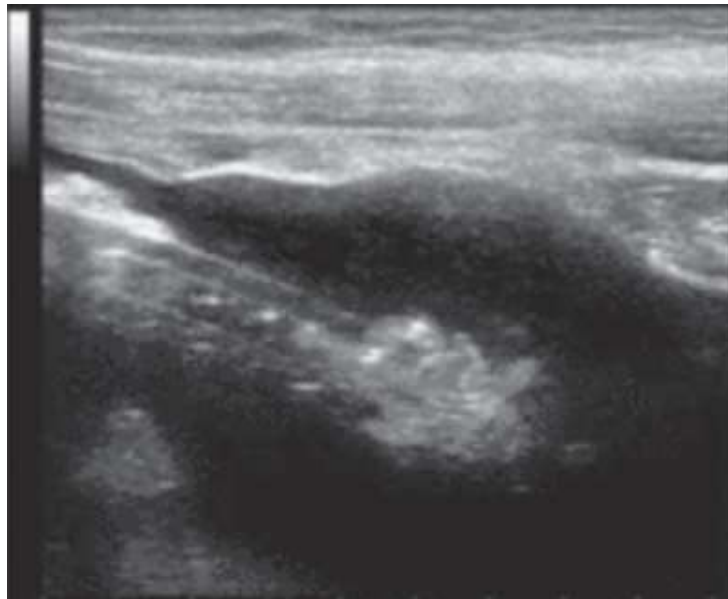
# Catheter-related pain –INFLOW

- Possible mechanisms
  - Catheter pressure on abdominal organs/ with omental wrap
  - Jet effect of rapid flow
- More common when intraperitoneal portion of catheter is straight c.f. coiled (*Twardowski & Nichols, 2000*)
- Rectal pain can occur when the intraperitoneal segment of the catheter is too long (*Prowant 2001*)



# Mechanisms of catheter-related pain - **OUTFLOW**

- May be related to tip of catheter coming into contact with parietal peritoneum
- May be due to omental trapping in the catheter as drainage proceeds



# Pain unrelated to catheter

- May be due to acidic pH ( 5.2-5.5) of conventional PD solutions
- Temperature
- Overdistension of abdomen at the end of inflow
  - Hyperosmolarity of PD solution
  - Large Dwell volumes

# Management of Infusion pain

- Reduce infusion rate
- Slowly increase fill volumes
- Warm dialysate solutions to body temperature
- Tidal volume (in APD) - leave some dialysate fluid when draining out
- Change from conventional PD fluid ( low pH) to more physiological PD solutions ( high pH)

# Outline

- TECHNICAL COMPLICATIONS
  - ❖ Catheter related
  - ❖ Related to increased intrabdominal pressure:
    - Hernias
    - Leaks
    - Hydrothorax
  - ❖ Haemoperitoneum
- METABOLIC COMPLICATIONS
- ENCAPSULATING PERITONEAL SCLEROSIS

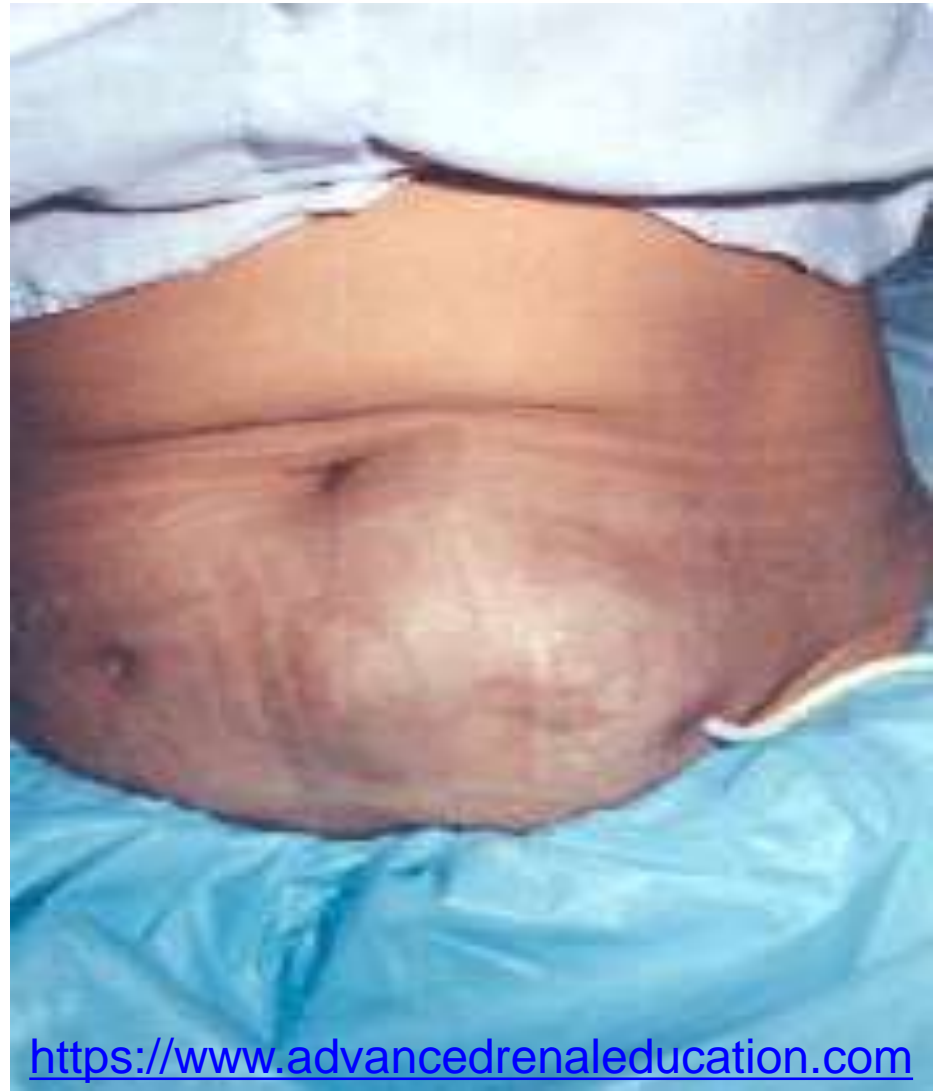## Case Scenario 2

- 42 year old gentleman with diabetes, undergone PD catheter insertion. 1 months after commence PD noted anterior abdominal swelling. Not painful.
- Ultrafiltration diminished for past 1 months and body weight increased by 3kg of given dry weight.

# Leaks

## Presentation:

- Wetness/swelling at Exit Site
- Anterior abdominal wall/genital oedema or halo formation (concealed)
- Poor ultrafiltration
- Weight gain without peripheral edema



# Pathogenesis of leaks

1. Dialysate can find its path through the soft-tissue plane from:
    - a. The catheter insertion site
    - b. Soft-tissue defect
    - c. Peritoneal-fascial defect
  2. Dialysate can travel via a patent processus vaginalis to the scrotum or labia.
- Beware of possible associated inguinal hernia - viscera may follow or accompanies the dialysate in its path through the processus vaginalis

# Leak

- Often related to:
  - Poor catheter implantation techniques : Attention to surgical recommendations on insertion location (paramedian approach) and positioning of internal cuff reduce the risk of leakage
  - Anatomical abnormalities
  - Using the catheter prior to healing
  - Trauma
- Patients at risk:
  - Patients with poor tissue healing (diabetics, elderly, malnourished, and those on corticosteroids)
  - Patients with increased intra-abdominal pressure



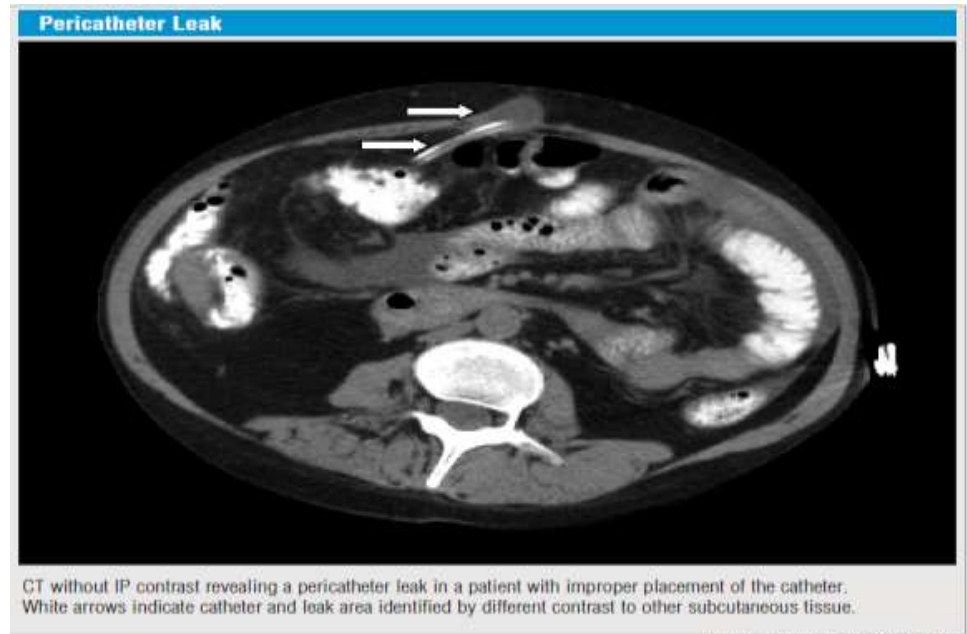
# Key activities

## External leaks:

- Verify that clear fluid at incision or exit site contains glucose, using glucose test strip
- Document condition of exit site, subcutaneous cuff, tunnel and/or wound
- Modify dressing change procedure to accommodate increased fluid drainage – e.g. if have ascites, drain daily
- Consider prophylactic antibiotic administration to prevent peritonitis

# Imaging Techniques

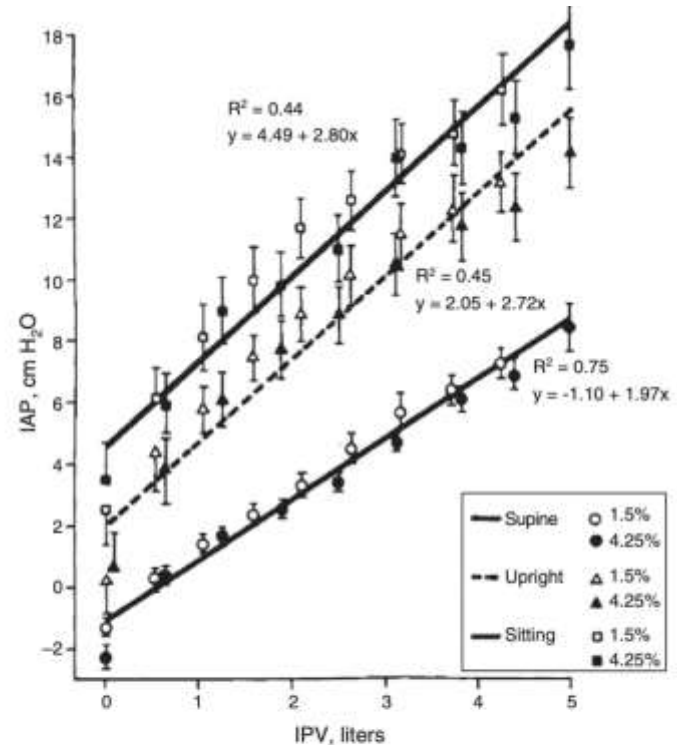
- CT peritoneography
- Abdominal fluoroscopy with contrast
- Peritoneal scintigraphy
- Peritoneal MRI with dialysate as “contrast medium”



Radiograph courtesy of Ali Abu-Alla, MD

# Management of Leaks

- Delay initiation of PD training at least 3 weeks if possible ( rest peritoneum , try to avoid HD if adequate RKF)
- PD or APD in supine position; keep abdomen dry when not in supine position
- Low volume dialysate (500-1500 mls) dwell volume until leak has subsided
- Recurrent pericatheter leak may require new catheter placement



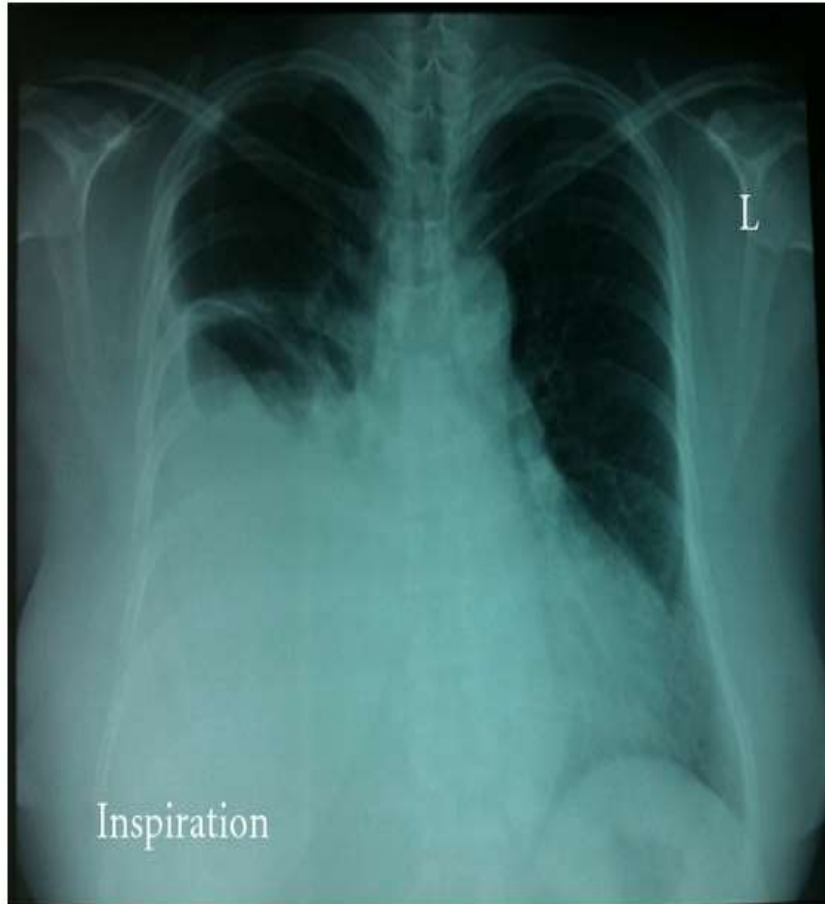
**Fig. 3 – Correlation between intraperitoneal pressure (IPP) and intraperitoneal volume (IPV) in different body positions, with glucose solutions 1.5 and 4.25% (mean ± SEM).**

Source: Twardowski et al.,<sup>8</sup> with permission.

# Case Scenario 3

- 56 years old lady, diagnosed ESRD with diabetes.
- On the 3<sup>rd</sup> day of PD training, she complained of cough and shortness of breath especially on lying down. PD flow was good.
- What is the possible problem?

# Pleural leak (hydrothorax)

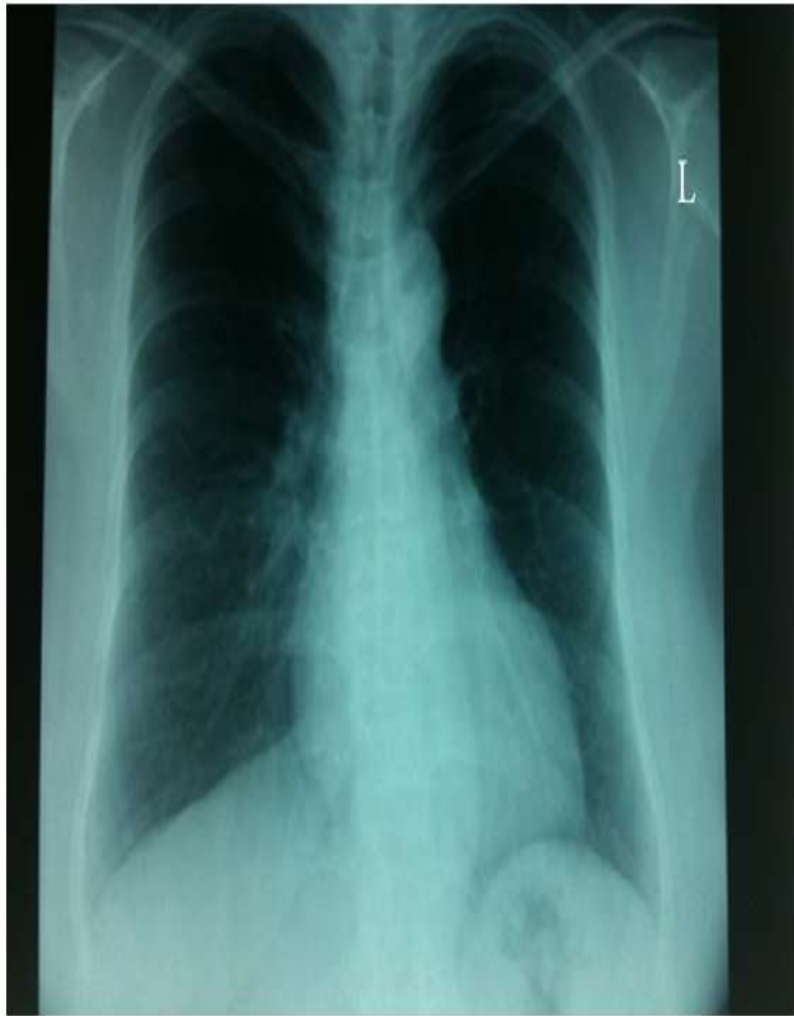

- CXR: (R) sided pleural effusion
- Movement of dialysate from peritoneal to pleural cavity through congenital or acquired defects in diaphragm

# Management

- Pleural tap: Symptomatic and diagnostic purposes
- Pleural analysis: transudate, high glucose concentration

- Stop PD (4-6 weeks) with temporary HD
- May be able to re-try PD - low volume in upright position → seal off the connection
- Pleurodesis (talc, tetracycline, bleomycin, autologous blood)
- Operative or pleuroscopic repair



- Trial of restarting PD with low dwell volume

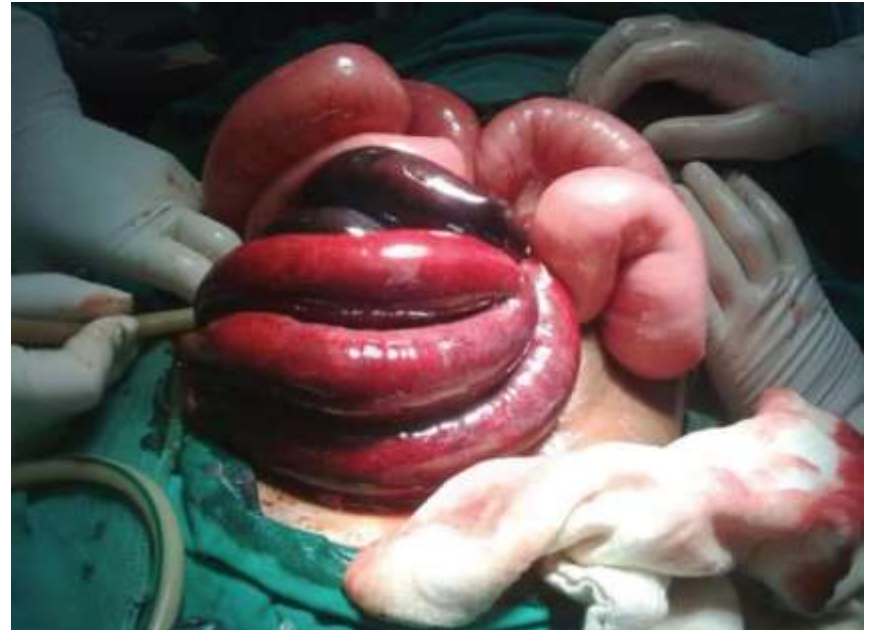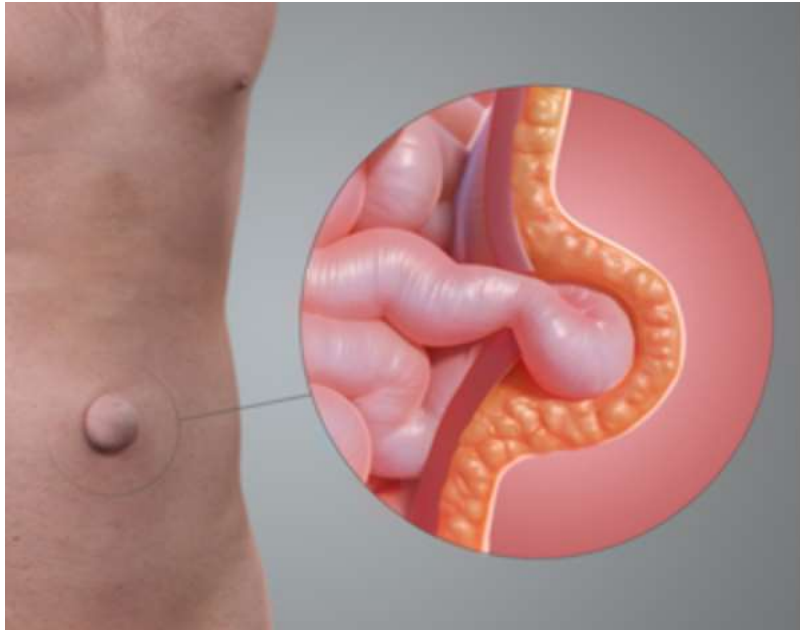
Chest x-ray after 4 weeks

## Case Scenario 4

- 68 year old man on CAPD for 2 years. Complaint of **umbilical swelling** with pain and vomiting for 2 days.
- No history of fever.
- PD fluid clear. Ultrafiltration good.



# Hernias



- Present as a lump/swelling that may be tender
- Reported prevalence ranges from 9% -32% in most series.
- In recent years, the paramedian approach to catheter placement has reduced the incidence of exit site and incisional herniae. → umbilical hernia have become the most common type of hernia a/w PD
- Risk of incarceration or strangulation if small outlet

# Risk Factors for hernia:

- Older patients
- Time on PD - annual ↑d risk of 20% for each year on PD
- Previous hernia repair
- Previous laparotomies
- Polycystic kidneys
- Intra-abdominal masses
- Collagen diseases
- Obesity
- Small body size
- Malnutrition

# Management

- Educate and warn patient on signs of bowel incarceration
- Supine CAPD or APD
- Surgical repair
  - Depending on your surgeon/ patient's RKF- withhold PD for several days to weeks to allow proper healing and to avoid postoperative dialysate leakage from hernia repair site / early hernia recurrence

# Management

- Tension-free hernia repair with polypropylene mesh reinforcement may allow the patient to commence or continue PD as early as 24 h after surgery<sup>1</sup>
- Even without mesh repair, may be able to avoid temporary vascular access catheter – D/W the surgeon about reintroducing PD at low volume with a gradual increase in dwell volume

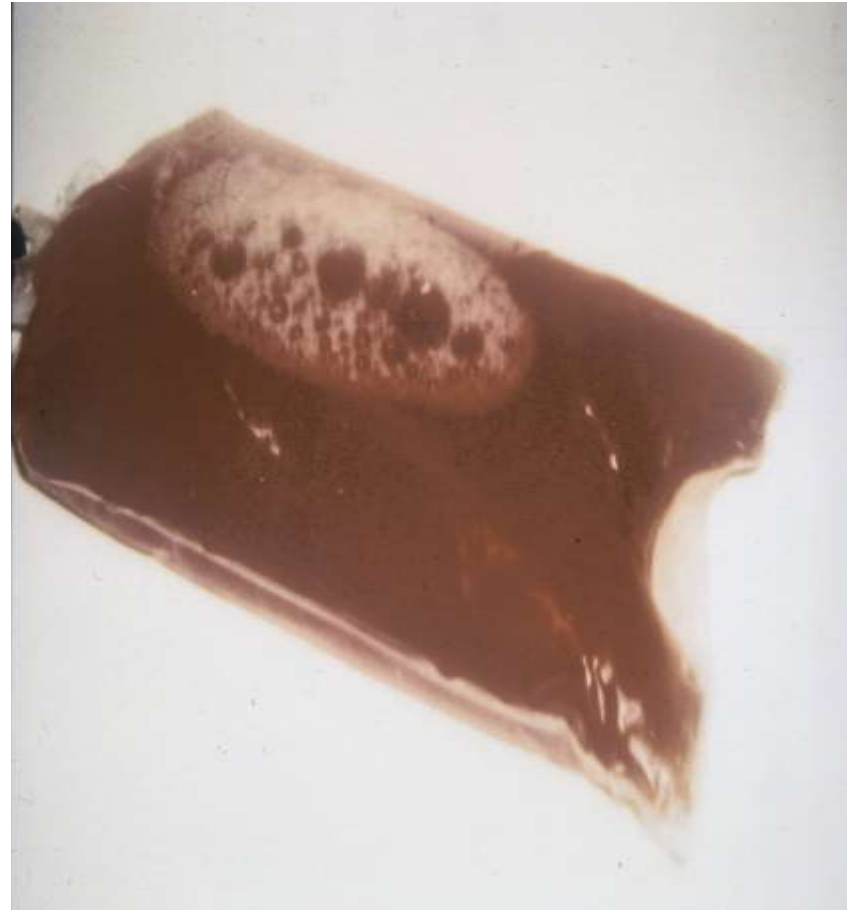e.g. use low dwell volumes 1L via cyclor for week 1 post-op  
increase to 1.5L in week 2  
resume normal prescription thereafter<sup>2</sup>

1. Gianetta E, Civalleri D, Serventi A, Floris F, Mariani F, Aloisi F, et al. Anterior tension-free repair under local anesthesia of abdominal wall hernias in continuous ambulatory peritoneal dialysis patients. *Hernia* 2004;8:354-7

2. Crabtree JH. Hernia repair without delay in initiating or continuing peritoneal dialysis. *Perit Dial Int* 2006;26:178-82

# Haemoperitoneum

- In women: most common cause is retrograde menstruation and ovulation
- Catheter induced trauma
- Strenuous exercise
- Formation of adhesions
- Urologic cancers



# Management

- Rule out peritonitis
- Flushing of catheter and IP heparin to prevent blood clots
- Investigate cause(s)

# Case Scenario 6

- 48 years old lady with ESRD and diabetes. Commenced on CAPD for 6 months.
- On SC Humulin 30/70 48 unit OM, 32 unit ON. Noted blood sugar persistently high despite high dose insulin therapy. Claim compliant to insulin therapy and diet control. Weight increased 4kg over 6 months. Not fluid overloaded.

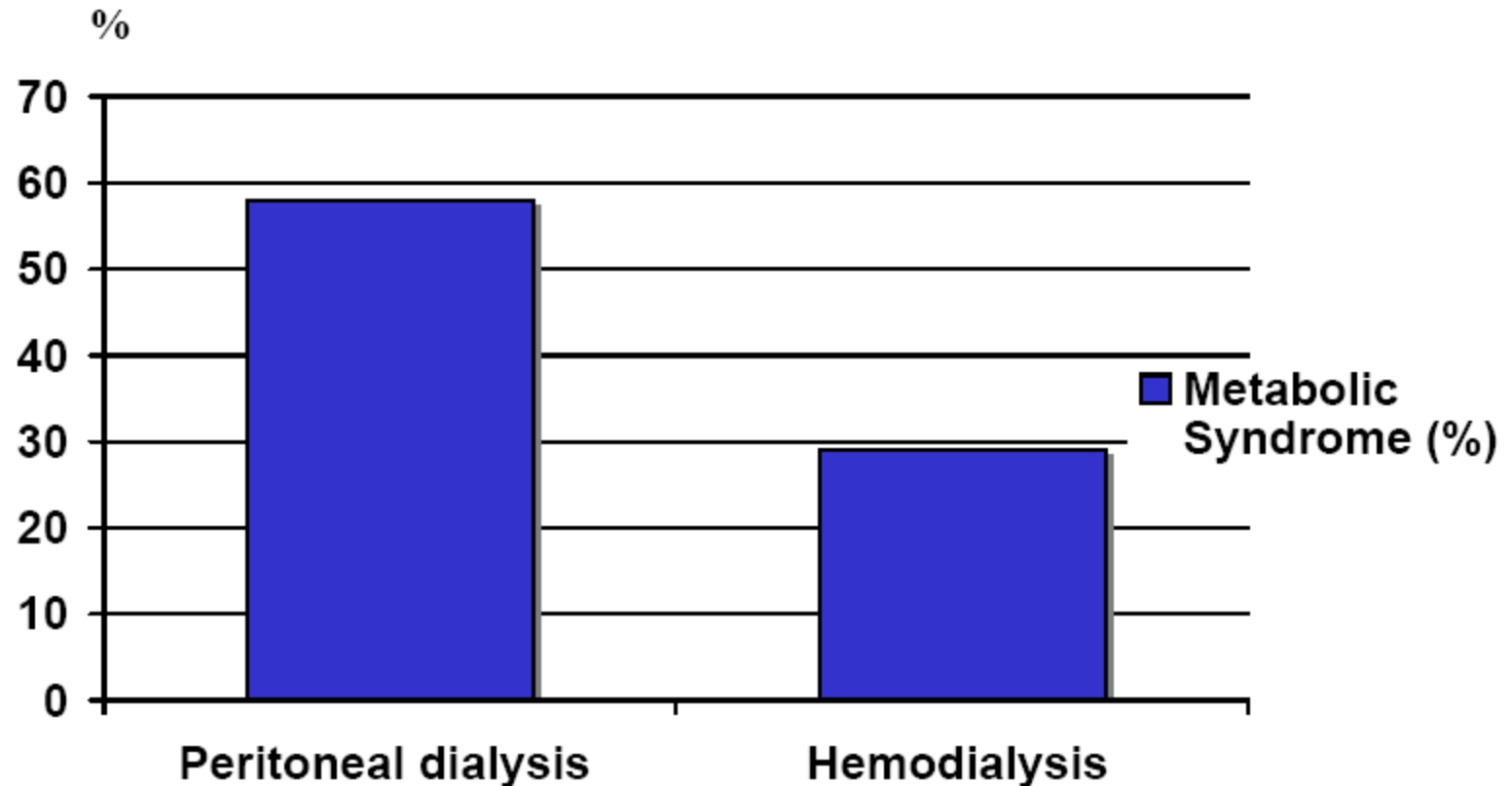
# Outline

- TECHNICAL COMPLICATIONS ( common)
  - ❖ Catheter related
  - ❖ Related to increase intrabdominal pressure:
    - Hernias
    - Leaks
    - Hydrothorax
  - ❖ Haemoperitoneum
- METABOLIC COMPLICATIONS
- ENCAPSULATING PERITONEAL SCLEROSIS



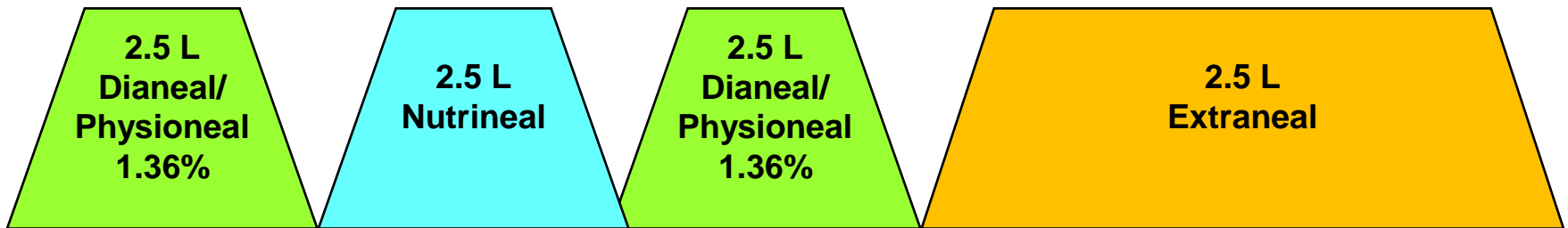
# Metabolic Syndrome and Dialysis

---

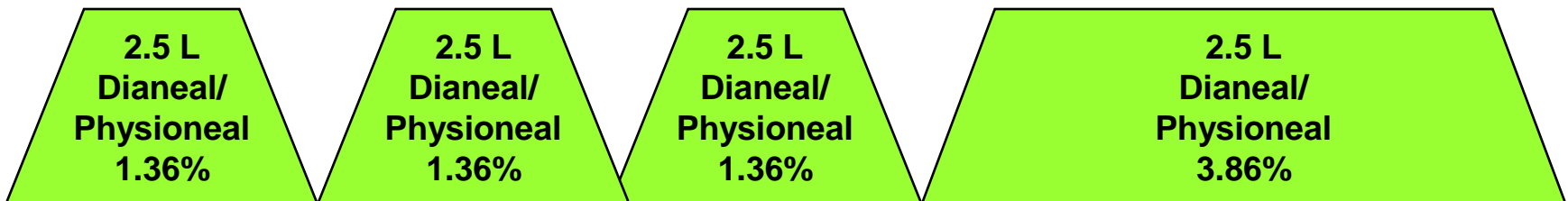


# Absorption of glucose from peritoneal solutions

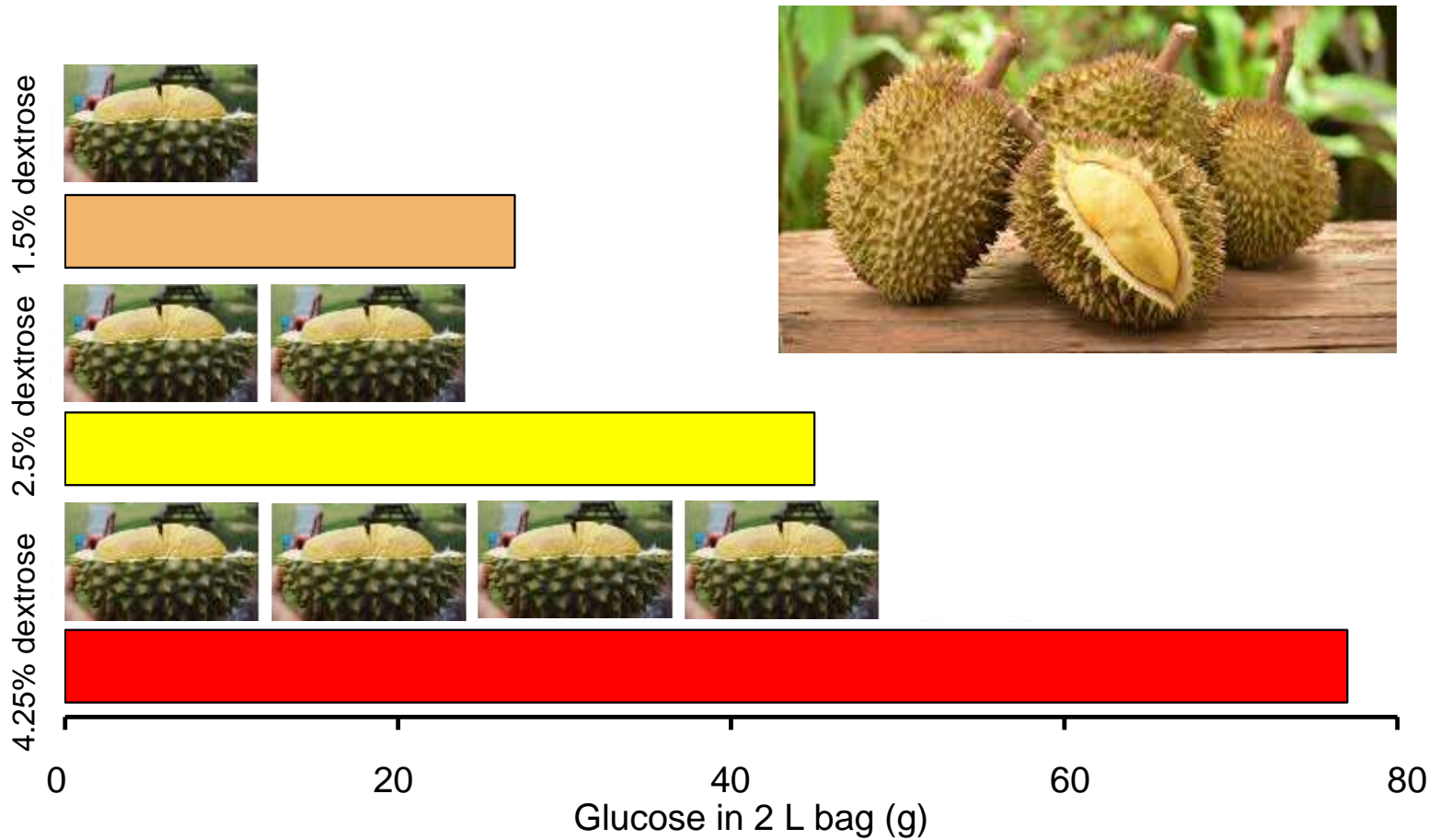
Glucose absorbed = 50 g/day



Glucose absorbed = 159 g/day



# “Adrian Liew equivalent”

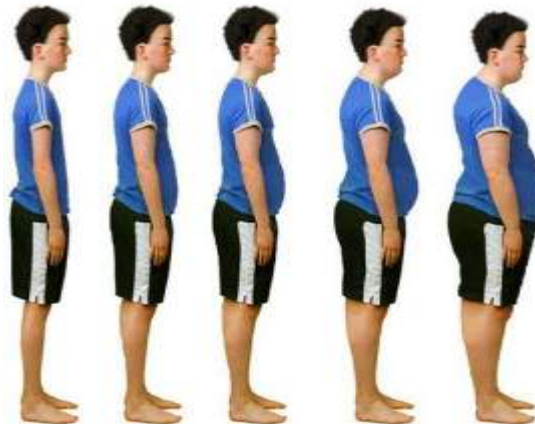


*Slide courtesy of Dr. Adrian Liew, TTSH*

# Metabolic complications of PD

- Hyperglycemia
- Hypertriglyceridemia
- Hyperinsulinemia
- Obesity

} Hyperleptinemia  
- inflammation and  
↓ lean body mass



# Strategies to Reduce Metabolic Complications



- Reduce peritoneal glucose loading
  - avoid using hypertonic glucose solution
  - use glucose-sparing dialysate eg. Icodextrin

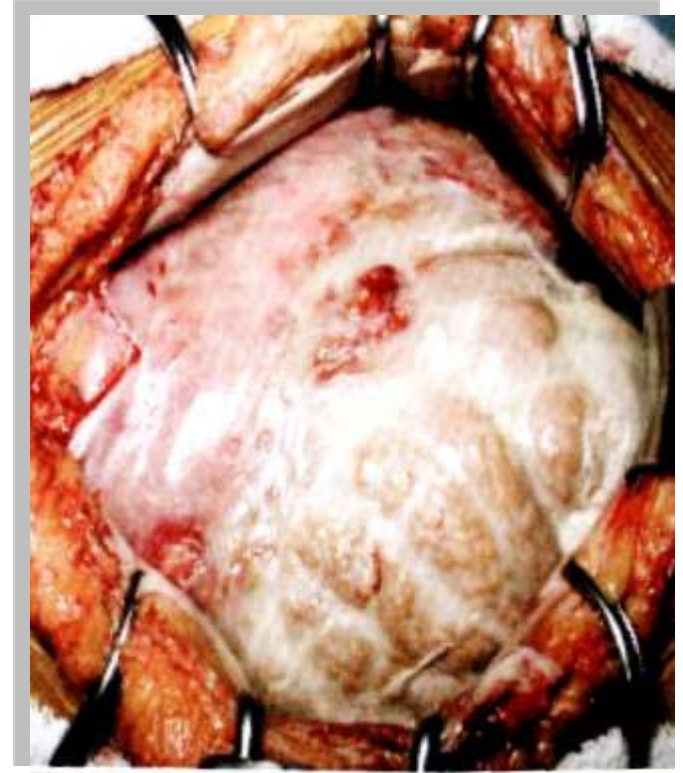
# Case Scenario 7

68 years old man ESRD with Diabetes

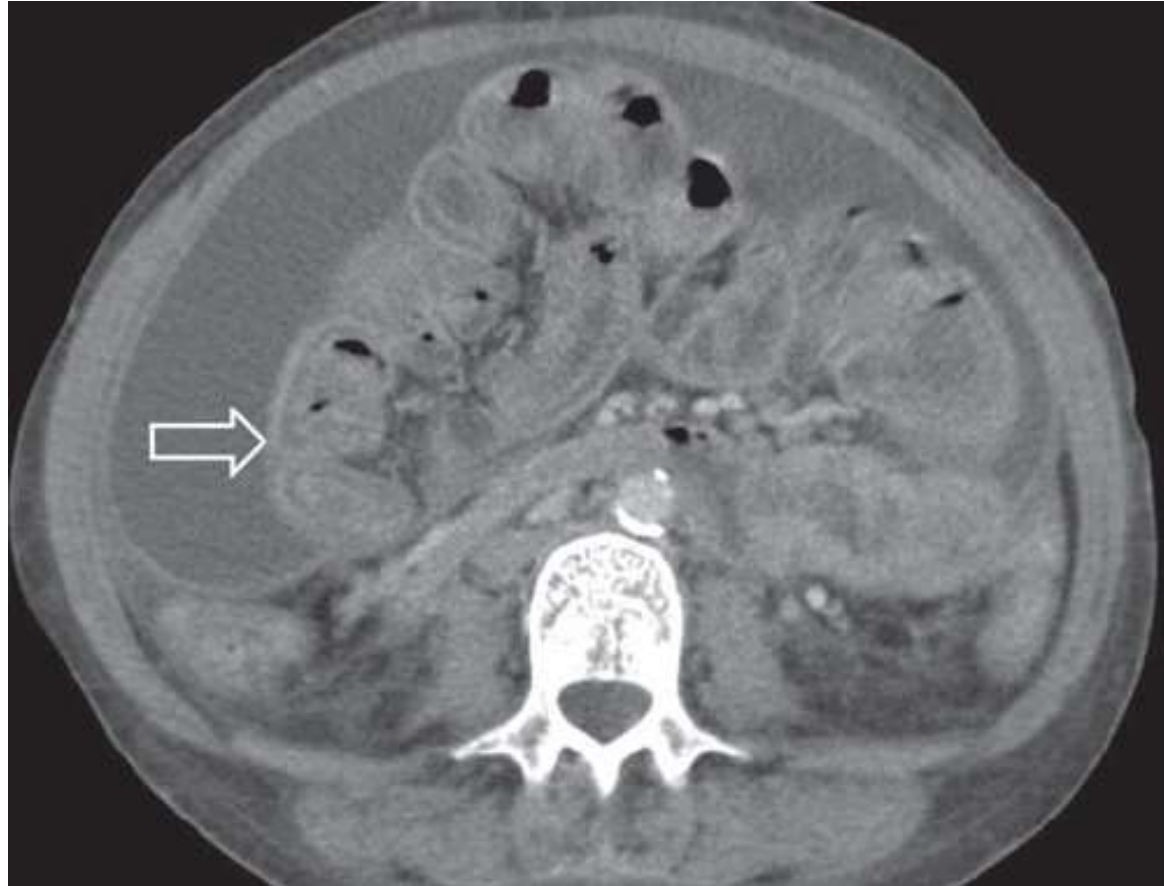
- On CAPD for 8 years
- History of multiple episodes of peritonitis →  
Using hypertonic PD solution for better ultrafiltration.
- Complains of abdominal distension, poor appetite, loss of weight, frequent vomiting
- What is causing him these symptoms?

# Encapsulating Peritoneal Sclerosis

- Rare but potentially devastating complication of PD
- Incidence: 0.5-7.3%, increasing with time on PD
- Diagnosis: Both clinical features of bowel obstruction/GIT symptoms with bowel encapsulation on radiological examination



# CT scan findings



Small-bowel wall is thickened and small-bowel loops are dilated (*arrow*). *Small-bowel loops are enclosed by fibrotic peritoneum*



# Management of EPS

- Nutrition is an crucial factor in the morbidity and mortality associated with EPS : early dietetic referral for nutritional enteral/parenteral support is important
- No clear evidence to support medical therapy - corticosteroids, immunosuppressants, tamoxifen have been used
- Surgical intervention is recommended if clinical symptoms of EPS persist

# Recommendations

- Pre-emptive switching to HD after specified time on PD is NOT recommended
- PD should usually be discontinued after diagnosis of EPS, with transfer to HD

# Conclusion

- Non-infectious complications are a challenge for PD practitioner
- With icodextrin and improved antidiabetic phamacotherapy, metabolic complications may be attenuated
- Similarly, there is a suggestion that EPS incidence may be on the decrease with more bio-compatible /low GDP PD solutions ( NEXT PD Study in Japan )

# Conclusion

- Catheter-related complications are therefore likely to remain the commonest complications
- Proper pre-operative assessment, good planning /timing & proper attention to PD catheter placement technique has the potential to reduce catheter malfunction substantially
- Will require a dedicated PD Access team and collaboration with the Surgical team

**Thank You**



# Clinical approach to catheter obstruction

## In case of fibrin-related obstruction:

- Add heparin 500 U/L to dialysate each exchange<sup>1</sup>
- Instill recombinant tissue plasminogen activator (tPA)<sup>2</sup>

## Administration of tPA:

- Prepare a solution of sterile water that has tPA 1 mg/mL
- Instill up to 8 mL (1–8 mg) after the filling of the abdomen with dialysis solution and allow to dwell for 1–2 hours. If the dialysate does not drain adequately, ensure that there is enough dialysate in the abdomen and re-instill the tPA at the same dose and allow to remain for an additional 90 minutes.
- Upon clearance of catheter, allow effluent to drain by gravity. Prior to initiating dialysis, the catheter may be flushed with sterile heparinized solution. Add antibiotics (first-generation cephalosporin preferred) to dialysate in following exchange.

1. Gokal R, et al. Peritoneal catheters and exit-site practices toward optimum peritoneal access: 1998 update. *Perit dial Int.* 1998;18:11-33.
2. Zorzanello M, et al. Use of tissue plasminogen activator in peritoneal dialysis catheters: a literature review and one centre's experience. *Neph Nurs J.* 2004;31:534-537.

# Criteria to diagnose MetS in PD

Requires 3 out of 5 criteria to fulfill diagnosis:

- Body mass index (BMI) > 30 kg/m<sup>2</sup> for Caucasians  
> 25 kg/m<sup>2</sup> for Asians
- Triglycerides > 1.7 mmol/L
- Low high-density lipoprotein cholesterol (<1.0 mmol/L in men; <1.3 mmol/L in women)
- Blood pressure (BP) > 130/85 mmHg or hypertension on treatment
- Fasting plasma glucose > 5.6 mmol/L or diabetes on treatment



# Obesity in PD

- Obese patient have higher risk of peritonitis
- High BMI with low muscle mass had higher CVS mortality
- Therefore PD patient should be encouraged to gain muscle mass rather than fat mass

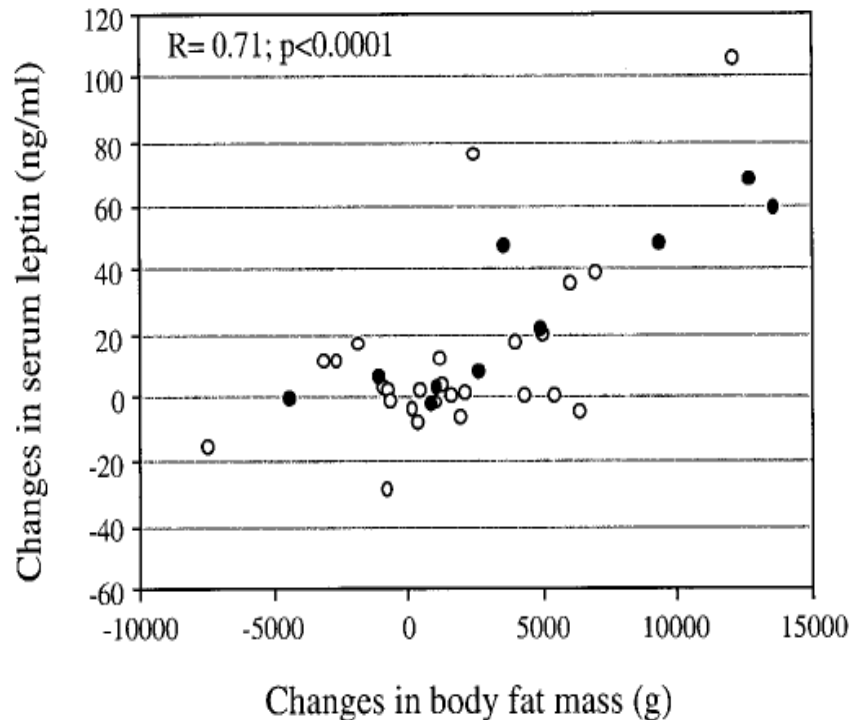


# Hyperleptinaemia

- Leptin
  - secreted from fat cells (adipose tissue)
  - regulates food intake & energy (appetite inhibitor)
  - good marker of amount of fat in obese & non-obese patient

# Serum leptin and PD

- PD is associated with marked increase in serum leptin
- Due to increase body fat mass & hyperinsulinemia
- Increase leptin is associated with inflammation and decreased lean body mass



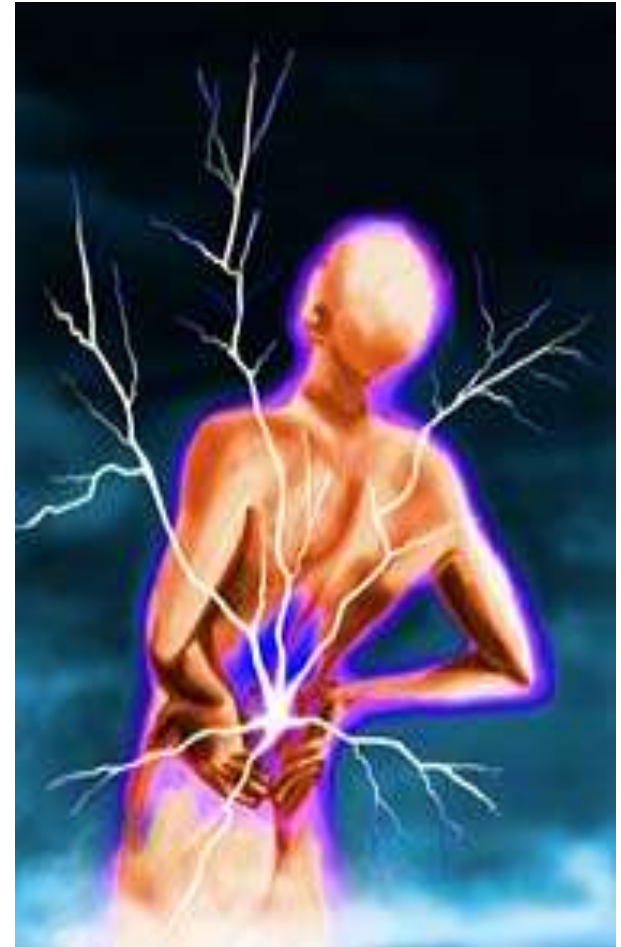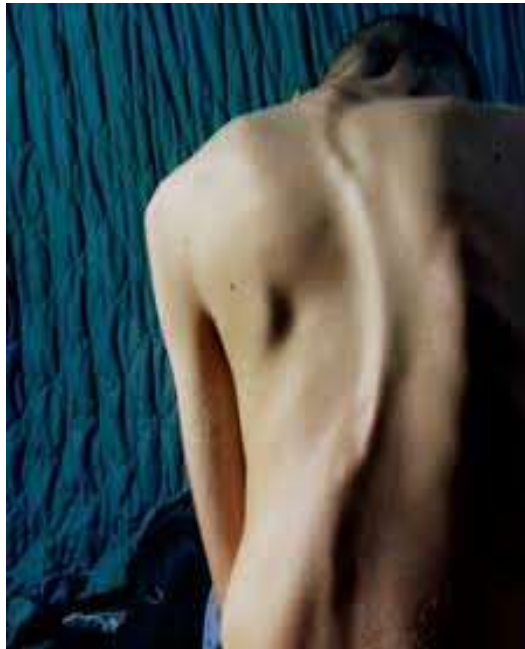**Changes in serum leptin and total body fat mass in diabetic (●) and nondiabetic**

**(○) patients treated by PD**

Stenvinkel et al, JASN 2000 : 11(1303-1309)

# Complications related to increased abdominal pressure

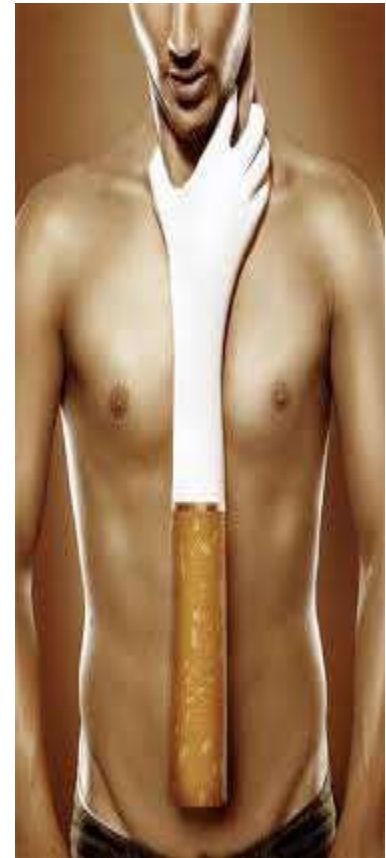- Back pain



# Related to increase abdominal pressure(2)

Splinting of diaphragm:

- Chronic Obstructive Airway Disease(COAD)
- Reduced lung volume




# Diagnosis by CT scan

- Add 100-150 mls contrast to dialysis bag and instill into patient peritoneum
- Patient ambulate for 30-60 minutes
- Proceed for CT scan

# Metabolic Syndrome (MetS)

Cluster of clinical traits:

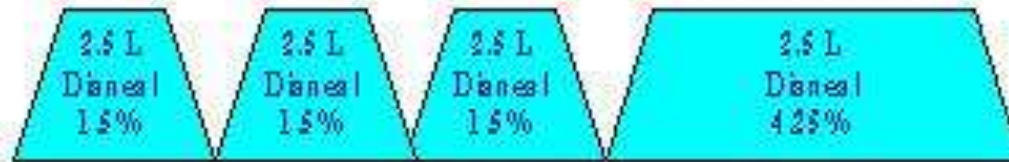- Abdominal obesity
- High BP
- Insulin resistance
- Dyslipidaemia



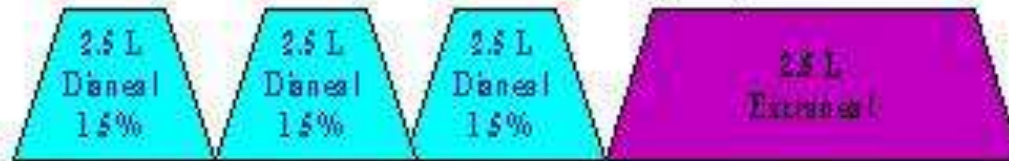Increase risk to develop overt diabetes, CVD and CKD and cardiovascular mortality

# Glucose load between different CAPD regime

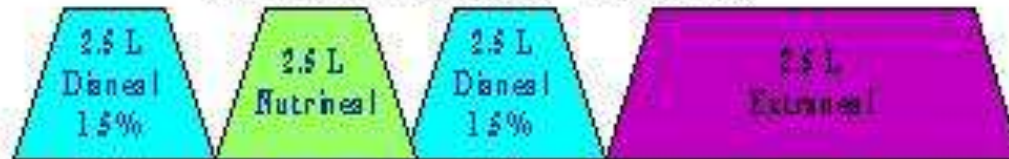**Glucose absorbed = 159 g/day**



**Glucose absorbed = 75 g/day**



**Glucose absorbed = 50 g/day**





# Hyperglycaemia

- Hyperglycemia and hyperinsulinemia responsible for altered haemodynamics
- Insulin resistance was significantly higher in PD patients (47%) than in HD (21%) or pre-dialysis patient (26% )

# Hyperlipidaemia

- Are associated with better nutritional status
- Paradoxical effect- cholesterol or BMI reflects better clinical outcome in PD patient

# Key assessment

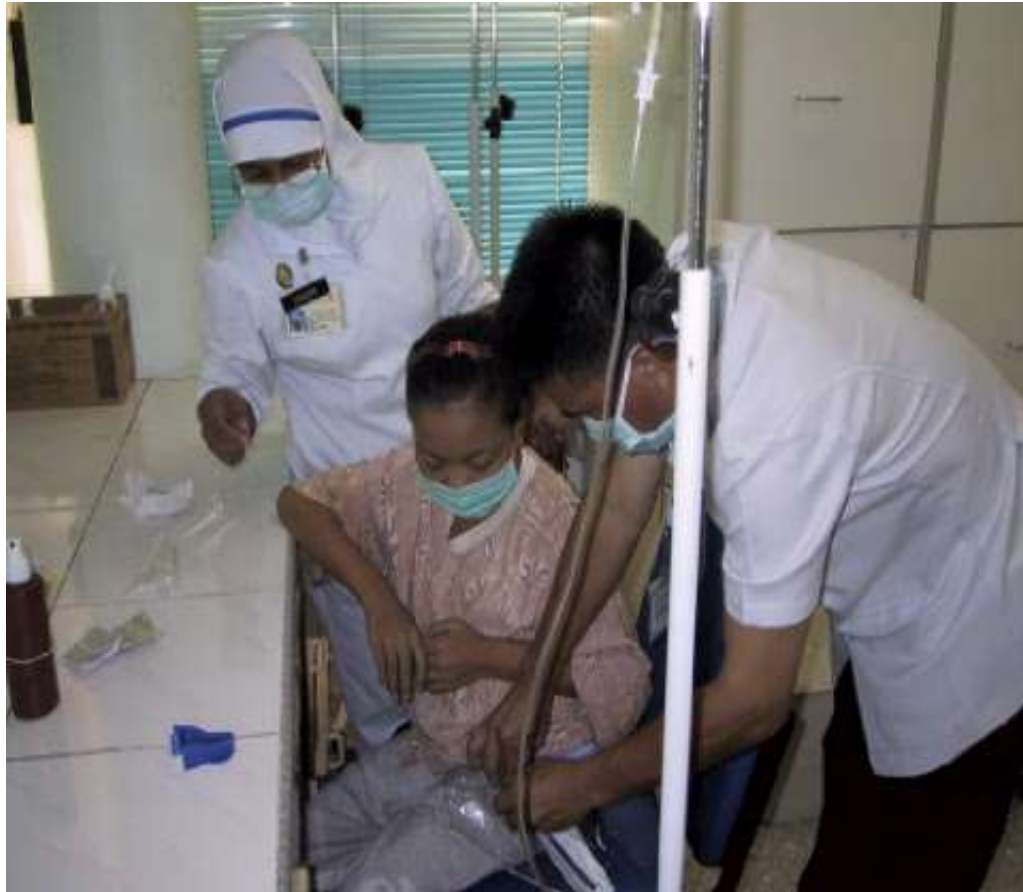- Careful history taking

## Key activities

- Change position during infusion/drain
- Reduce dialysis infusion rate ( lower IV pole, close transfer set clamp partially)
- (warm dialysis fluid to body temperature)
- AXR for catheter position
- Tidal PD
- IP xyloocaine 1%/ bicarbonate PD solutions → cost : increased risk of peritonitis, therapy burden and cost
- Minimise use of hypertonic dialysate solutions and reduce dwell volumes
- Reposition of PD catheter if unresolved

# Patient education

- Teach patient causes and interventions



# Patient education

- Tape or anchor catheter
- Prevent constipation with diet, exercise, stool softeners
- Position tubing to prevent kinking when sleeping on APD
- Provide written trouble-shooting directions to pt/care-giver

# **Organised clinical pathways to assist troubleshooting PD catheter malfunction**

1. Key assessments - identify major clinical findings
2. Key activities/actions – to achieve desired outcomes
3. Patient education – to provide pts/caregivers with the necessary education and/or tools to achieve desired outcomes
- ( 4. Outcomes assessments – use CQI to track and trend, to monitor and improve clinical outcomes)

# Outcomes Evaluation

Data to collect:

- Type of dysfunction
- Diagnostic testing
- Etiology
- Interventions
- Response to interventions

# Conclusion

- PD catheter dysfunction
  - not uncommon, esp.in first 90/7 of starting use of catheters
  - various forms
  - compromises delivery of dialysis
  - important impact on patient's wellbeing & quality of life
  - resource consumption



- Understanding various forms of PD catheter dysfunction and determining
  1. how to prevent
  2. how to solve themare critical to improving quality of care and outcomes for our patients.



THANK YOU

# CJASN<sup>®</sup>

Clinical Journal of American Society of Nephrology

Home

Content

Authors

Editorial Team

Subscriptions

More

---

Special Feature

## ✔ The 2010 Nephrology Quiz and Questionnaire: Part 2

Richard J. Glassock, Anthony J. Bleyer, Joanne M. Bargman and Fernando C. Fervenza

CJASN October 2011, 6 (10) 2534-2547; DOI: <https://doi.org/10.2215/CJN.06500711>

## **ESRD and Dialysis Case 2: Joanne M. Bargman (Discussant)**

The patient is a 74-year-old woman with CKD (stage 5) on the basis of diabetic nephropathy. She has been on continuous ambulatory peritoneal dialysis (PD) for the last 4 years. In her third year she had an episode of peritonitis that resolved quickly with antibiotics. Routine clinic visits in her fourth year had been unremarkable. However, one day the patient's daughter called the PD unit to report a problem with both inflow and outflow of the dialysate. They had noticed the flow to be slower for the past 3 days, and on the day of the phone call there was very little flow observed. The patient came to the unit and had a supine x-ray of the abdomen, which showed that the PD catheter was in good position in the deep pelvis. There was a moderate amount of feces in the colon. The patient was prescribed cathartics on the assumption that constipation was the cause of the catheter malfunction. However, even with several bowel movements and follow-up radiography showing clearing of the colon, there was still very poor inflow and outflow.

Which ONE of the following is LEAST likely to be the cause of the catheter dysfunction?

A. Constipation.

B. Intraluminal clot of the PD catheter.

C. Encapsulating peritoneal sclerosis (EPS).

D. Kink in the PD catheter.

E. Omental wrap of the catheter.

- The patient, who is now anuric, has now been 4 days without dialysis. She feels well, but her BP is 150/105 mmHg, and her potassium is now 6.0 mEq/L
- ALL of the following steps could be taken EXCEPT which ONE
  - A. Catheter study with radiocontrast media.
  - B. Immediate catheter placement for hemodialysis.
  - C. Oral potassium exchange resin for the hyperkalemia.
  - D. Peritoneal dialysis catheter removal and replacement.
  - E. Addition of an angiotensin converting enzyme inhibitor for the hypertension

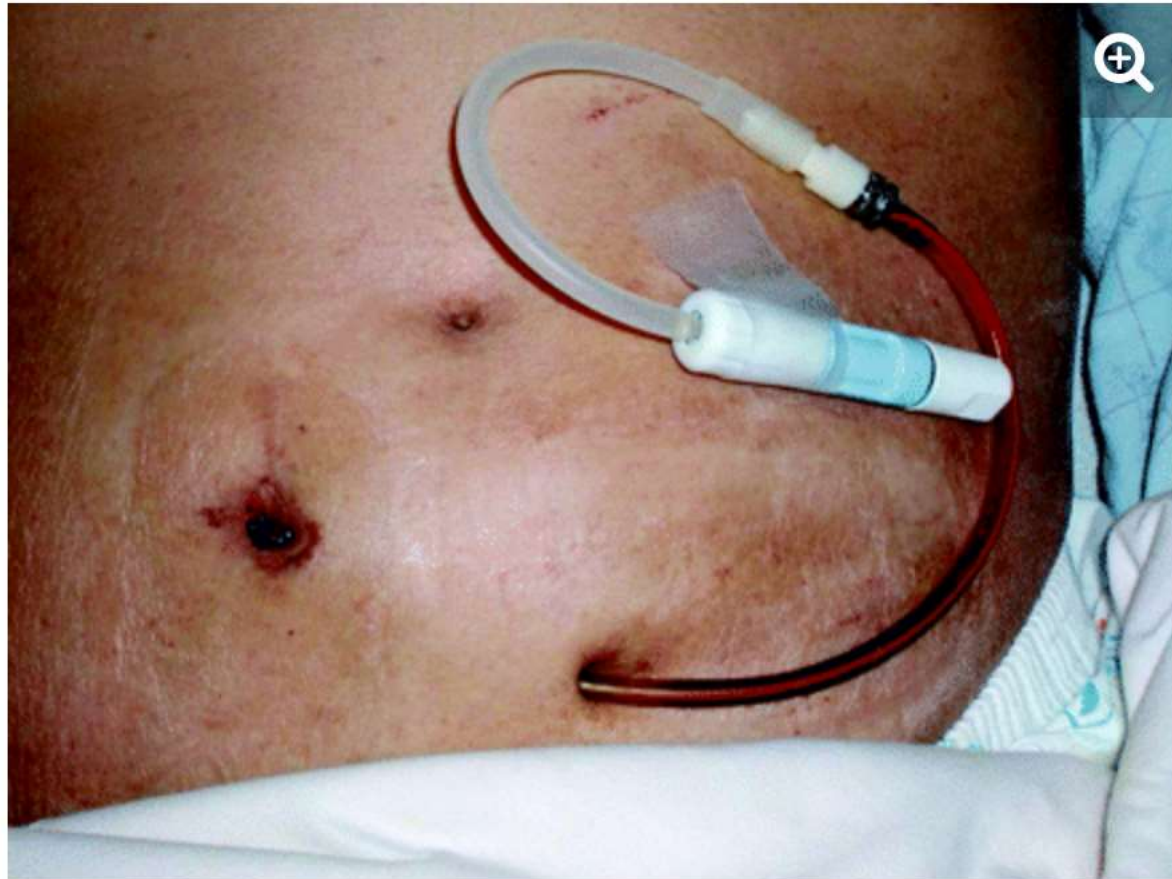- All of the other choices are reasonable for this patient.
- She was v. opposed to temporary HD, so attempts were made to try to repair and return function to the PD catheter.
  - a catheter radiocontrast study which surprisingly showed a patent PD catheter : radiocontrast material injected through the catheter traveled freely into the peritoneal cavity with no evidence of intraluminal obstruction
- Because unable to elucidate the cause of the catheter dysfunction, the patient was scheduled for an urgent PD catheter removal and replacement the next day

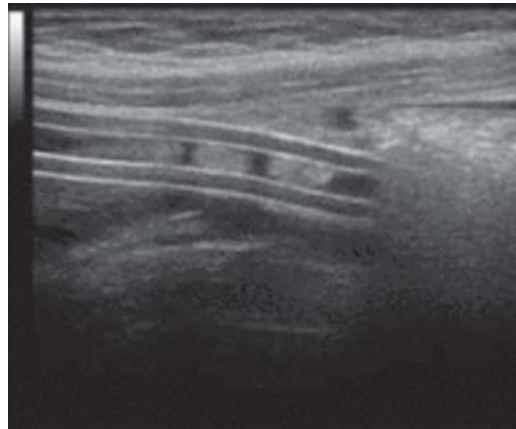- Meanwhile, PD nurse suggests
  - A. Instill tissue plasminogen activator (tPA) into the catheter lumen.
  - B. Change the catheter transfer set and connector.
  - C. Use a stronger cathartic.
  - D. Change from a coiled to a straight intraperitoneal portion of the catheter when it is replaced.
  - E. Use icodextrin instead of conventional peritoneal dialysis solution



- The transfer set was removed and a flush of dialysate through the catheter showed normal inflow and outflow.
- The transfer set was replaced with a new one, and inflow and outflow remained unimpeded.
- The problem that caused the obstruction in the first place was an accumulation of fibrin in the transfer set (for the radiocontrast study, the radiologist removed the transfer set to inject the dye, and that is why the study showed normal inflow)
- However, the old transfer set was put back onto the catheter, and the problem recurred.

# Configuration of PD catheter , connector and transfer set



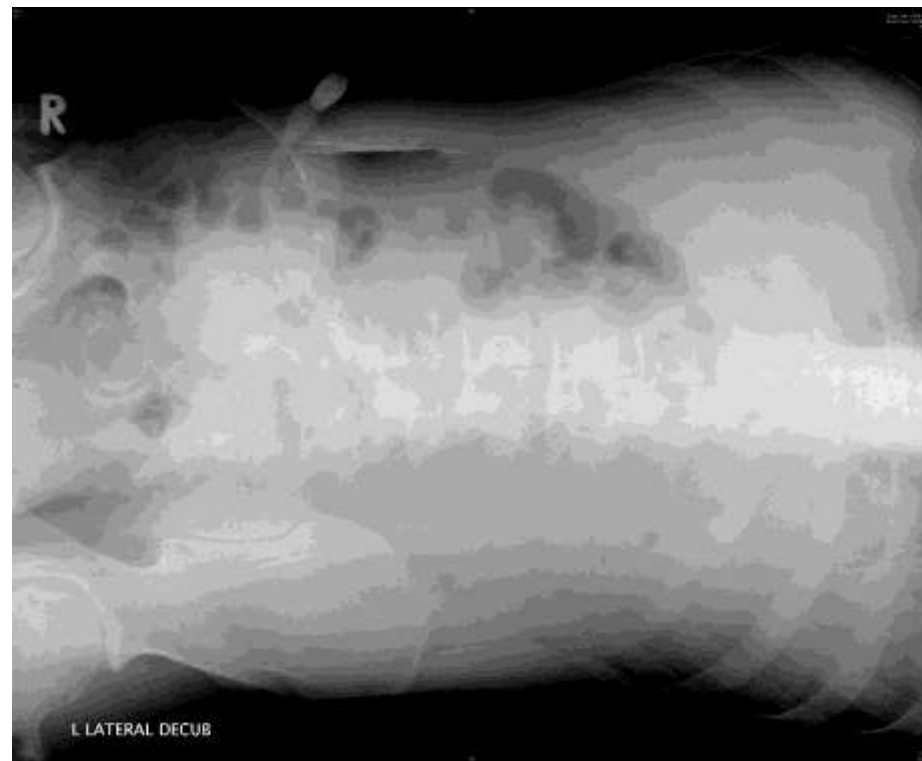
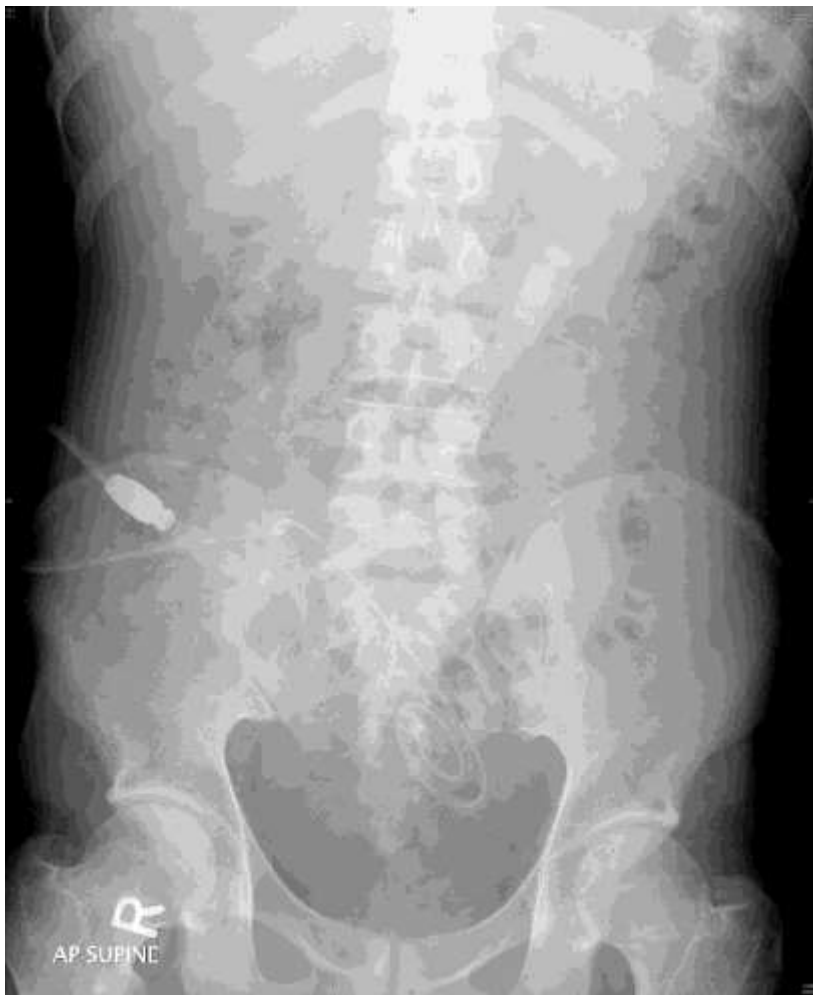
**Figure 1 | The 'sandwich structure' of Tenckoff catheter with endoluminal scattered internal echoes corresponding to strands of fibrin.**

## No standard protocol for thrombolytic agents to de clot PD caths

- If the flushing is not successful, 7 mg of tPA (1 mg/ml) is instilled into the catheter followed by 1 mg every 15 minutes for another 3 mg and then left overnight
- Recipe for urokinase : 7500units in 5 mls N saline , left to dwell 2 H

# Catheter kink



noted kink between deep and superficial cuffs.

# Organised clinical pathways to assist troubleshooting PD catheter malfunction

1. Key assessments - identify major clinical findings
2. Key activities/actions – to achieve desired outcomes
3. Patient education – to provide pts/caregivers with the necessary education and/or tools to achieve desired outcomes
- ( 4. Outcomes assessments – use CQI to track and trend, to monitor and improve clinical outcomes)

# Fluoroscopic Manipulation of Peritoneal Dialysis Catheters: Outcomes and Factors Associated with Successful Manipulation

Matthew Miller,\* Brendan McCormick,<sup>†</sup> Susan Lavoie,<sup>‡</sup> Mohan Biyani,<sup>‡</sup> and Deborah Zimmerman<sup>†\*</sup>

## Summary

**Background and objectives** Mechanical failure of the peritoneal dialysis (PD) catheter is an important cause of technique failure. Fluoroscopic guidewire manipulation may be undertaken in an attempt to correct the failure. The purpose of this study was to determine the efficacy of fluoroscopic manipulation of previously embedded PD catheters, the factors associated with successful manipulation, and the complication rate associated with manipulation.

**Design, setting, participants, & measurements** A single-center, retrospective review of 70 consecutive PD patients undergoing fluoroscopic manipulation for mechanical failure of their PD catheter from June 2006 to February 2011 was undertaken. Logistic regression models were developed to determine the variables associated with successful manipulation.


**Results** Of the 70 manipulations, 44 were successful (62.9%). In univariate analysis, catheters located in the pelvis compared with those in the upper abdomen (73.5% versus 42.9%,  $P=0.01$ ) and catheters that were previously functional compared with those that failed at exteriorization (75.0% versus 46.7%,  $P=0.04$ ) were more likely to be successfully manipulated. Time embedded, previous hemodialysis, and number of intra-abdominal surgeries were not correlated with likelihood of successful manipulation. In multivariate analysis, catheters located in the pelvis ( $P=0.01$ ) and those with secondary failure ( $P=0.01$ ) were more likely to be successfully manipulated. Two of the patients developed peritonitis (2.9%), neither requiring cessation of PD.

**Conclusions** Fluoroscopic manipulation is an effective and safe therapy for failed PD catheters that are unresponsive to conservative treatment. Properly positioned catheters and those that were previously functional are more likely to be successfully manipulated.

\*Division of Nephrology, McMaster University, Hamilton, Canada; <sup>†</sup>Division of Nephrology, University of Ottawa, Ottawa, Canada; and <sup>‡</sup>Kidney Research Centre of the Ottawa Hospital Research Institute, Ottawa, Canada

**Correspondence:** Dr. Deborah Zimmerman, Kidney Research Centre of the Ottawa Hospital Research Institute, 1967 Riverside Drive, Ottawa, ON K1H 7W9. Email: dzimmerman@ottawahospital.on.ca

# KIV throw



Different Types of Fogarty catheters



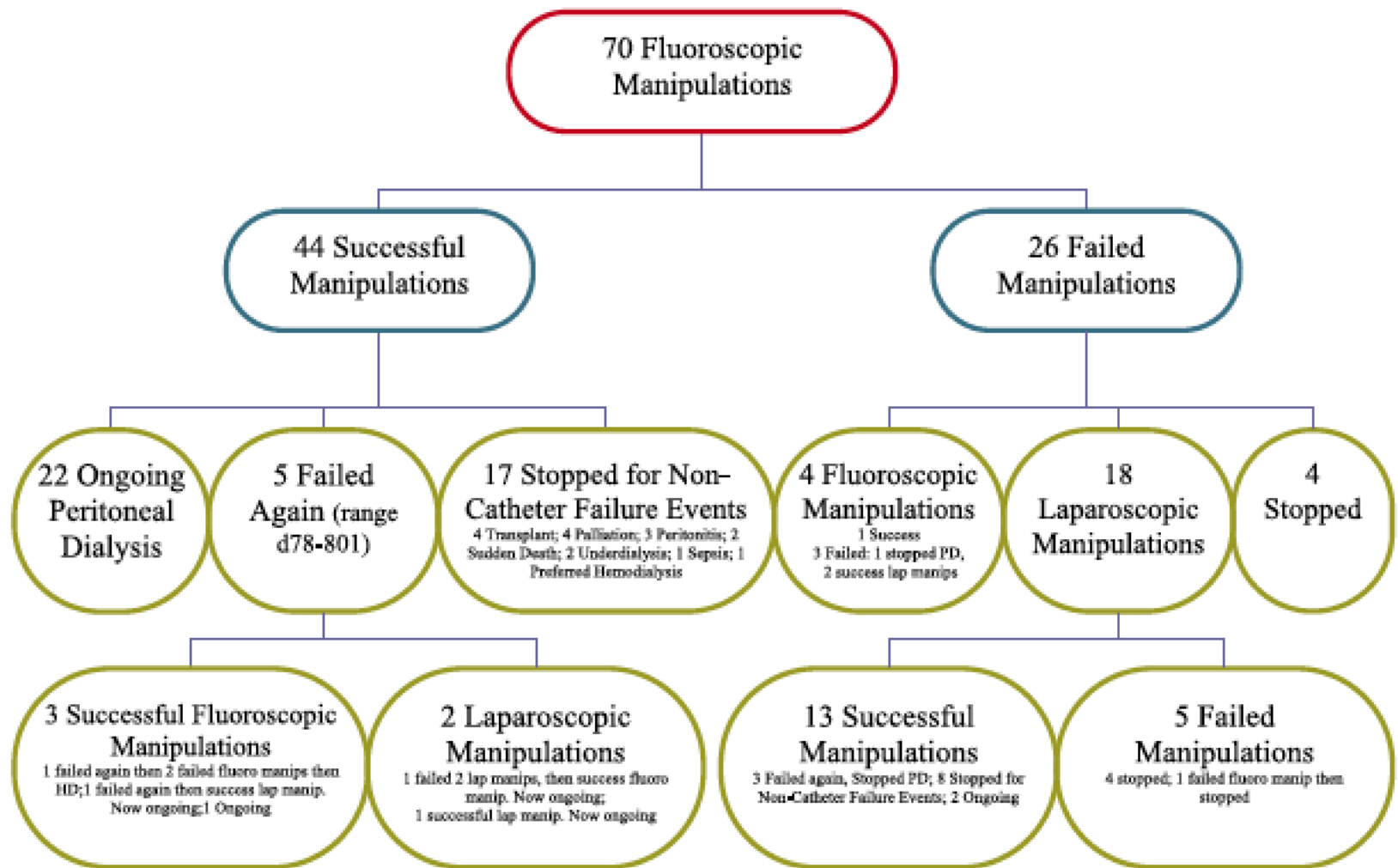


Figure 1. | Flowchart of individual patient outcomes after initial fluoroscopic manipulation.

**Results** Of the 70 manipulations, 44 were successful (62.9%). In univariate analysis, catheters located in the pelvis compared with those in the upper abdomen (73.5% versus 42.9%,  $P=0.01$ ) and catheters that were previously functional compared with those that failed at exteriorization (75.0% versus 46.7%,  $P=0.04$ ) were more likely to be successfully manipulated. Time embedded, previous hemodialysis, and number of intra-abdominal surgeries were not correlated with likelihood of successful manipulation. **In multivariate analysis, catheters located in the pelvis ( $P=0.01$ ) and those with secondary failure ( $P=0.01$ ) were more likely to successfully manipulated. Two of the patients developed peritonitis (2.9%), neither requiring cessation of PD.**

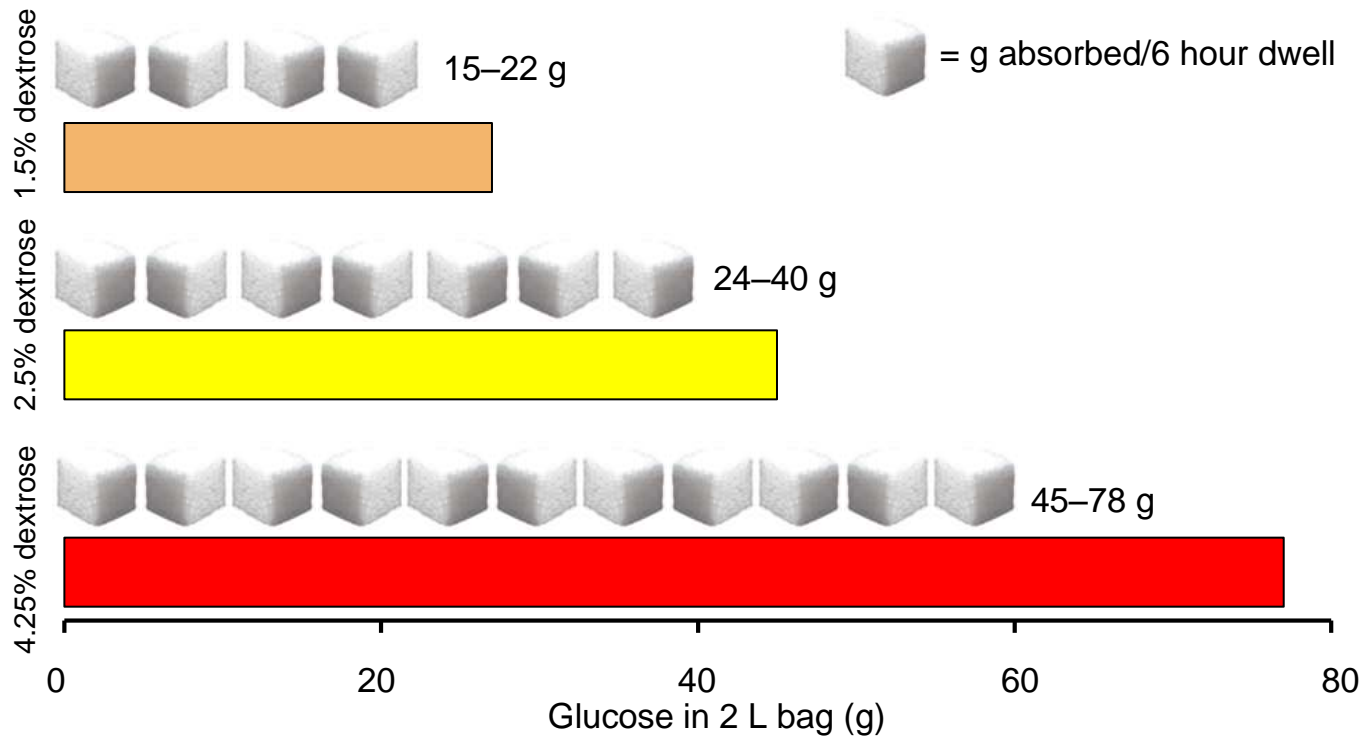
**Conclusions** Fluoroscopic manipulation is an effective and safe therapy for failed PD catheters that are unresponsive to conservative treatment. Properly positioned catheters and those that were previously functional are more likely to be successfully manipulated.

*Clin J Am Soc Nephrol* 7: ●●●–●●●, 2012. doi: 10.2215/CJN.09850911

# CONVENTIONAL PD SOLUTIONS **KIC THROW**

- Absorption of 100–200 g of glucose per day from conventional solutions worsens metabolic and nutritional problems:
    - impaired glucose tolerance
    - hyperinsulinemia
    - hyperlipidemia
- ± abdominal obesity.

→  cardiovascular risk , esp. in diabetic patients



*Lindholm B, Bergstrom J. In: Nolph KD, editor. Peritoneal Dialysis. Dordrecht: Kluwer, 1989. pp 230–60*